

**Implant placement simultaneous with full arch dental  
extraction and immediate occlusal loading**

**The Immediate Smile Procedure**

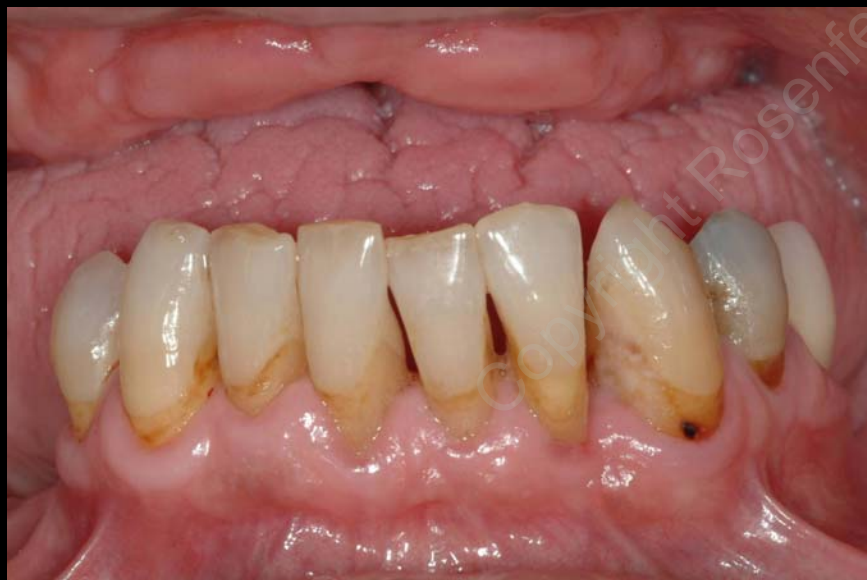**Drs. Alan Rosenfeld and George Mandelaris**  
Diplomates, American Board of Periodontology

# The Immediate Smile

## Implant placement + immediate occlusal loading

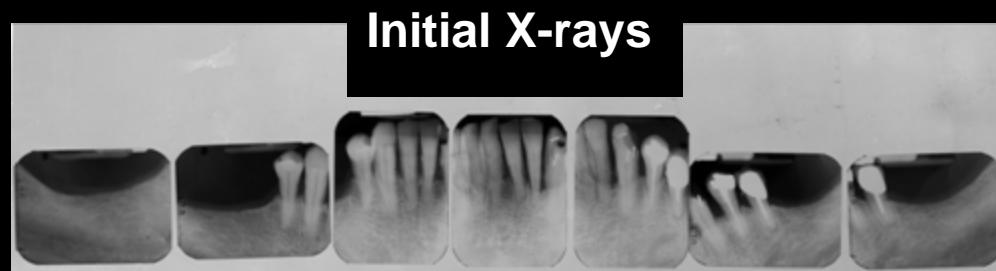
### Case Presentation

#### Initial Clinical Presentation



This picture demonstrates the patient's initial examination photo. These are the remaining teeth present, which have advanced periodontal disease as well as cavities.

**Prognosis: Questionable-Poor**



#### Initial X-rays

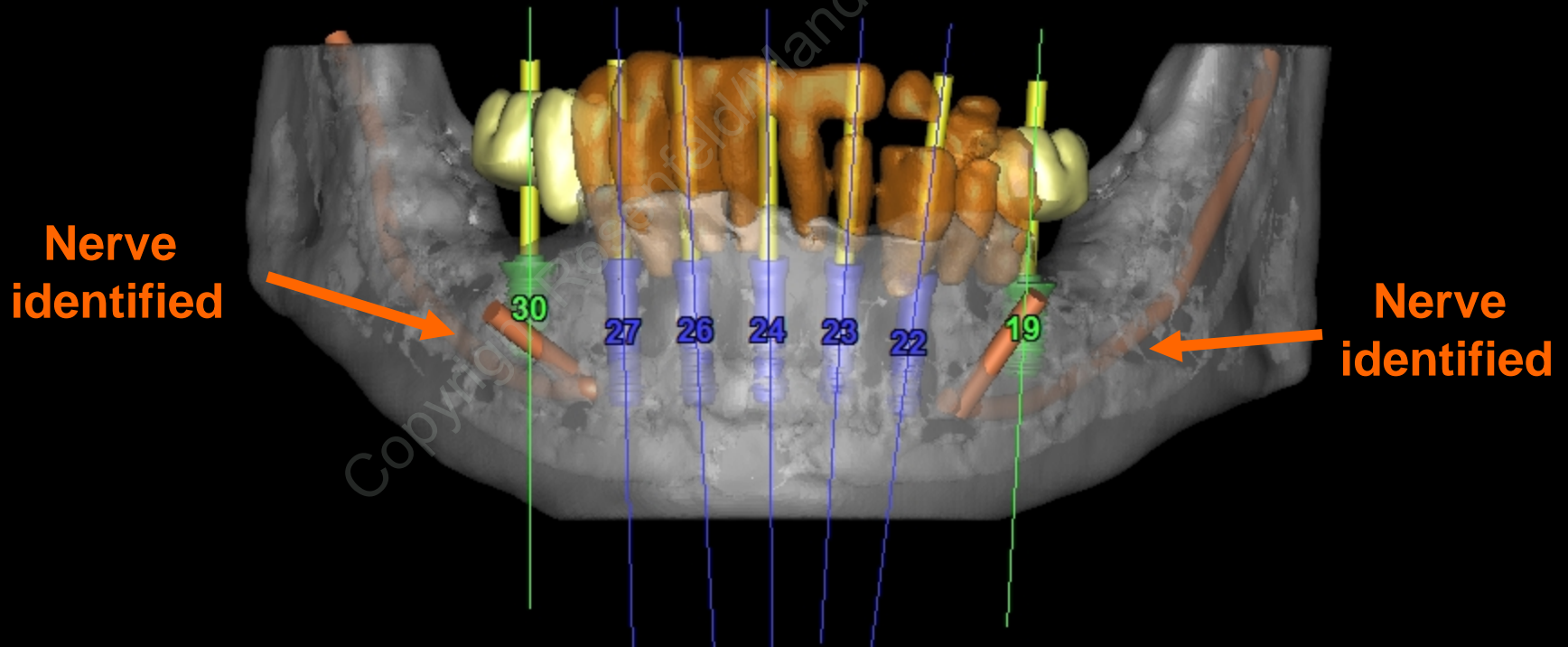
The radiographs confirm the clinical diagnosis and prognosis.

Treatment plan is to replace the mandibular natural dentition with an implant supported prosthesis. This replacement strategy will be similar to his real teeth, but negate the susceptibility characteristics that have affected his natural teeth so long as he is compliant with routine cleanings indefinitely.

# The Immediate Smile

Implant placement + immediate occlusal loading

## Case Presentation



CT Scan plan and 3D implant planning

CT guided surgery will be utilized to ensure precise implant placement

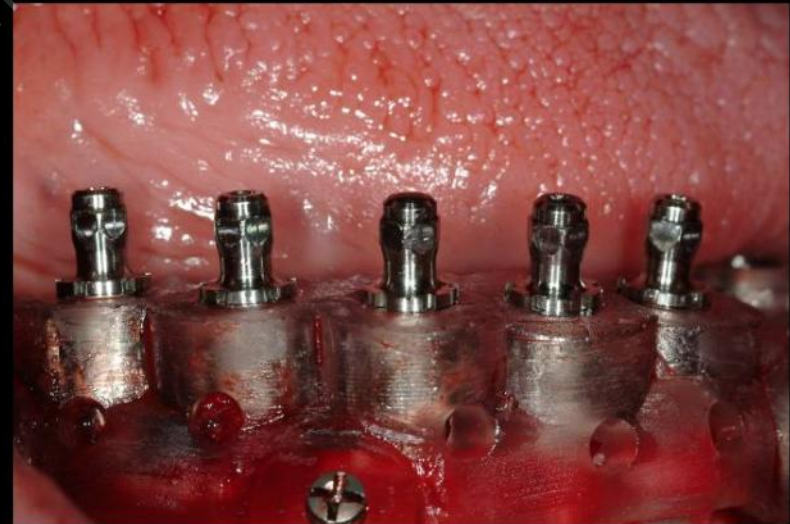# The Immediate Smile

Implant placement + immediate occlusal loading

## Case Presentation



CT scan technology utilized to create virtual duplicate of jawbone and a surgical guide developed from patients CT scan plan

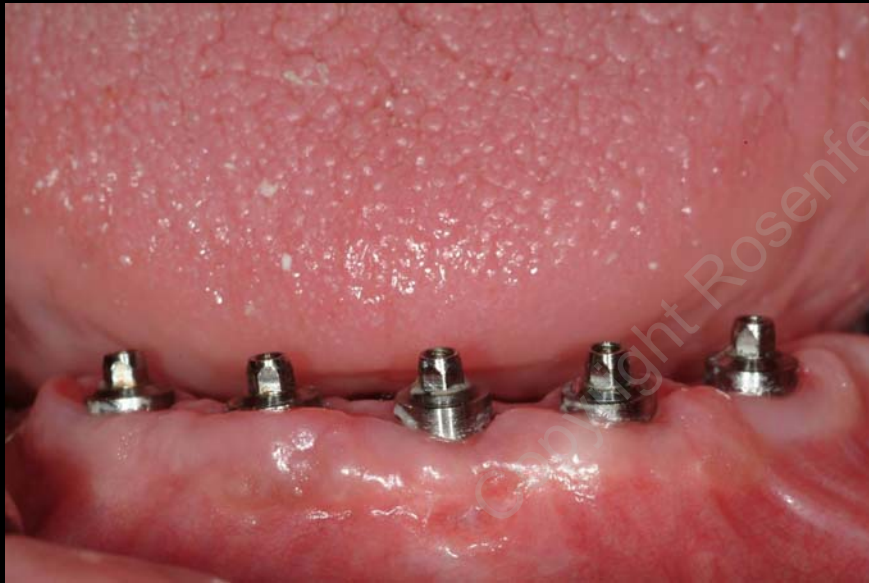

Extraction of hopeless teeth and application of CT guided technology for precision implant placement

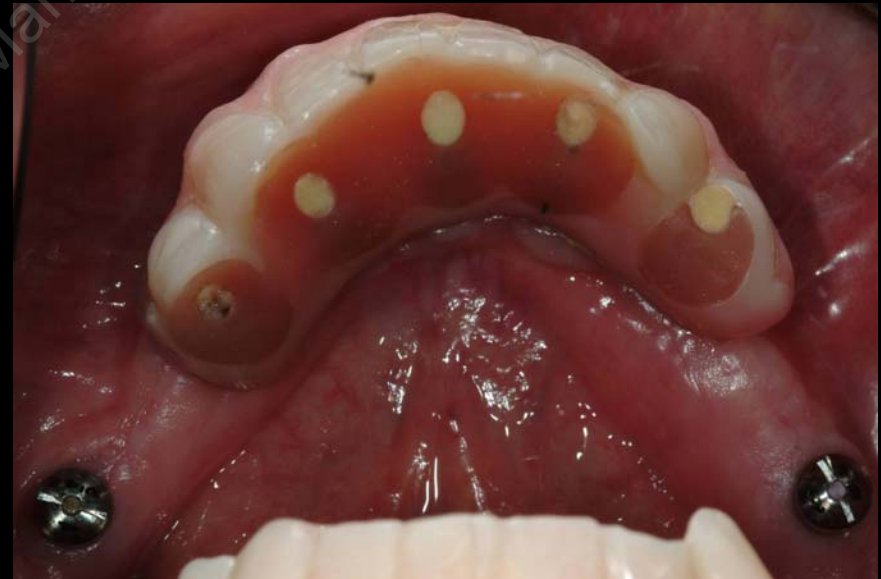# The Immediate Smile

Implant placement + immediate occlusal loading

## Case Presentation



12 weeks post surgery



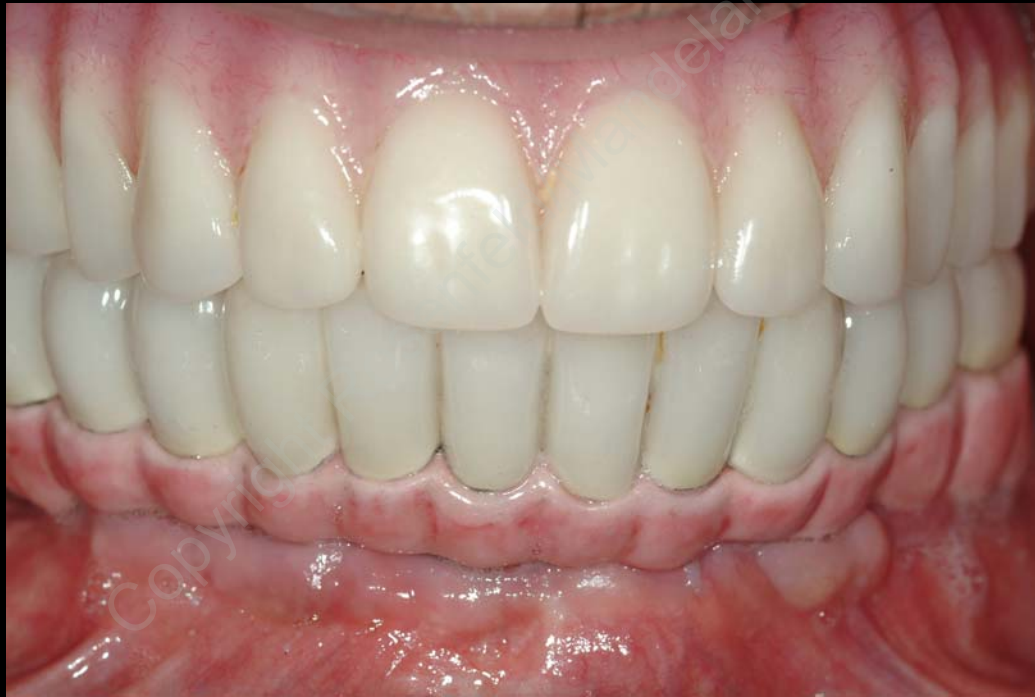Immediate teeth in place with other implants placed posteriorly & to be used with final teeth



# The Immediate Smile

Implant placement + immediate occlusal loading

## Case Presentation

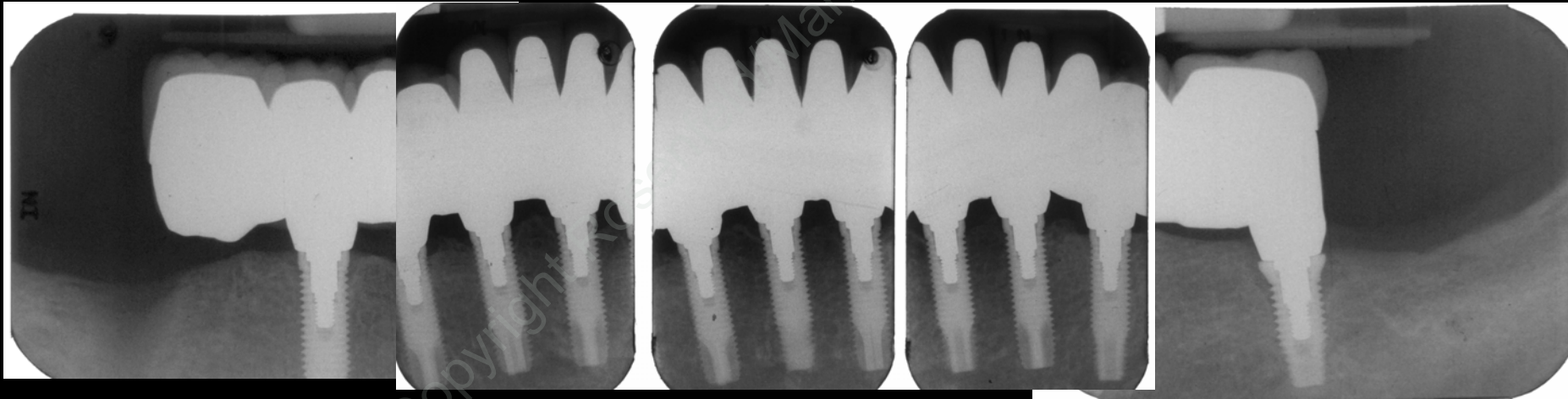


Clinical photo showing final prosthetic outcome of an implant supported fixed prosthesis in the mandible (bottom jaw) and a new denture for the maxilla (top jaw).

# The Immediate Smile

Implant placement + immediate occlusal loading

## Case Presentation



Final X-rays

In this case, 6 implants were used to support the full arch mandibular prosthesis which is fixed.