

SFOT

Re-defining the orthodontic walls...

Identifier: 32 years old caucasian

Chief complaint: "I am here because I am interested in getting braces and my orthodontist has recommended surgically facilitated orthodontic therapy as a way to treat my malocclusion, gingival recession. I am not willing to have jaw surgery."

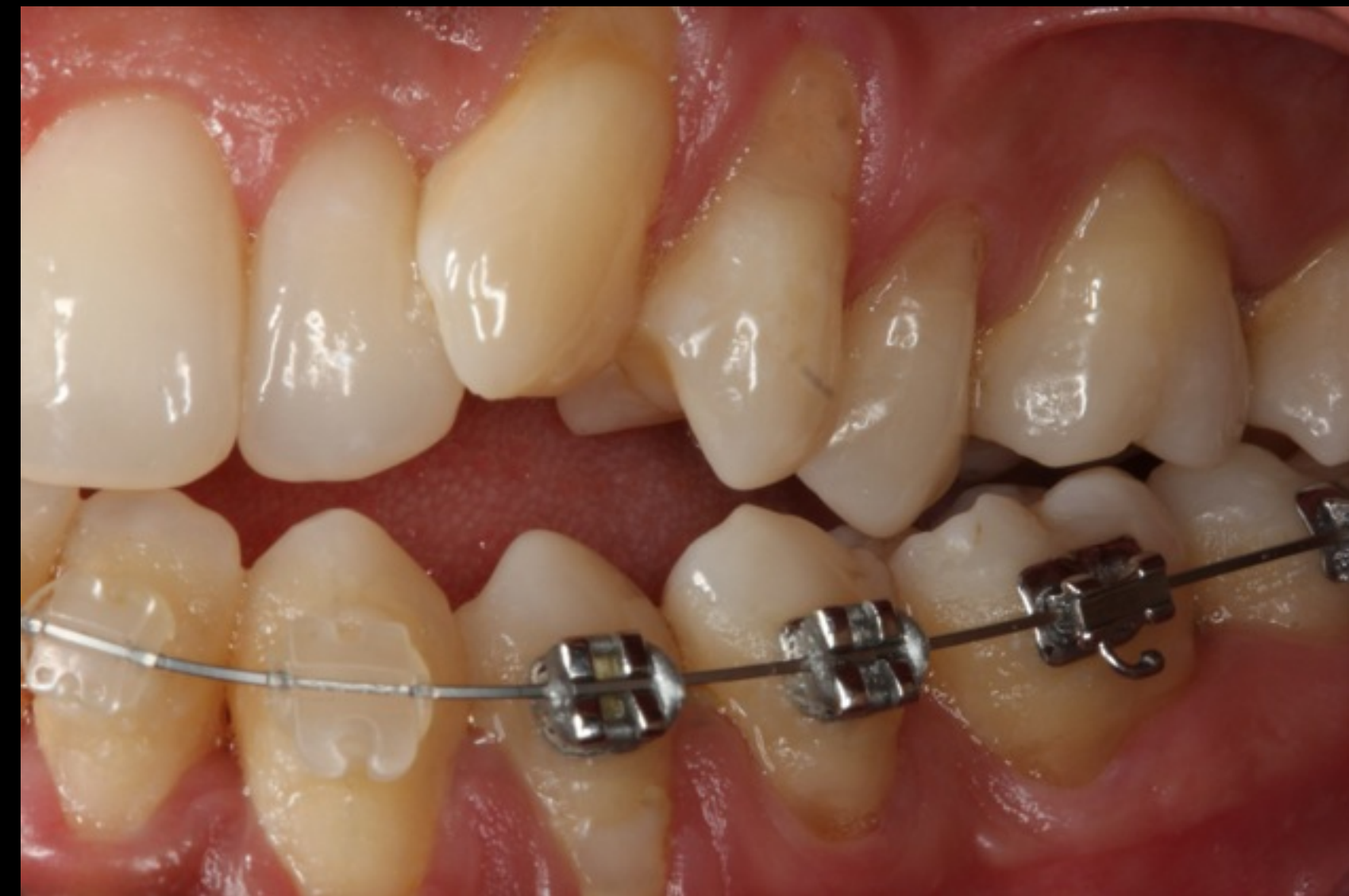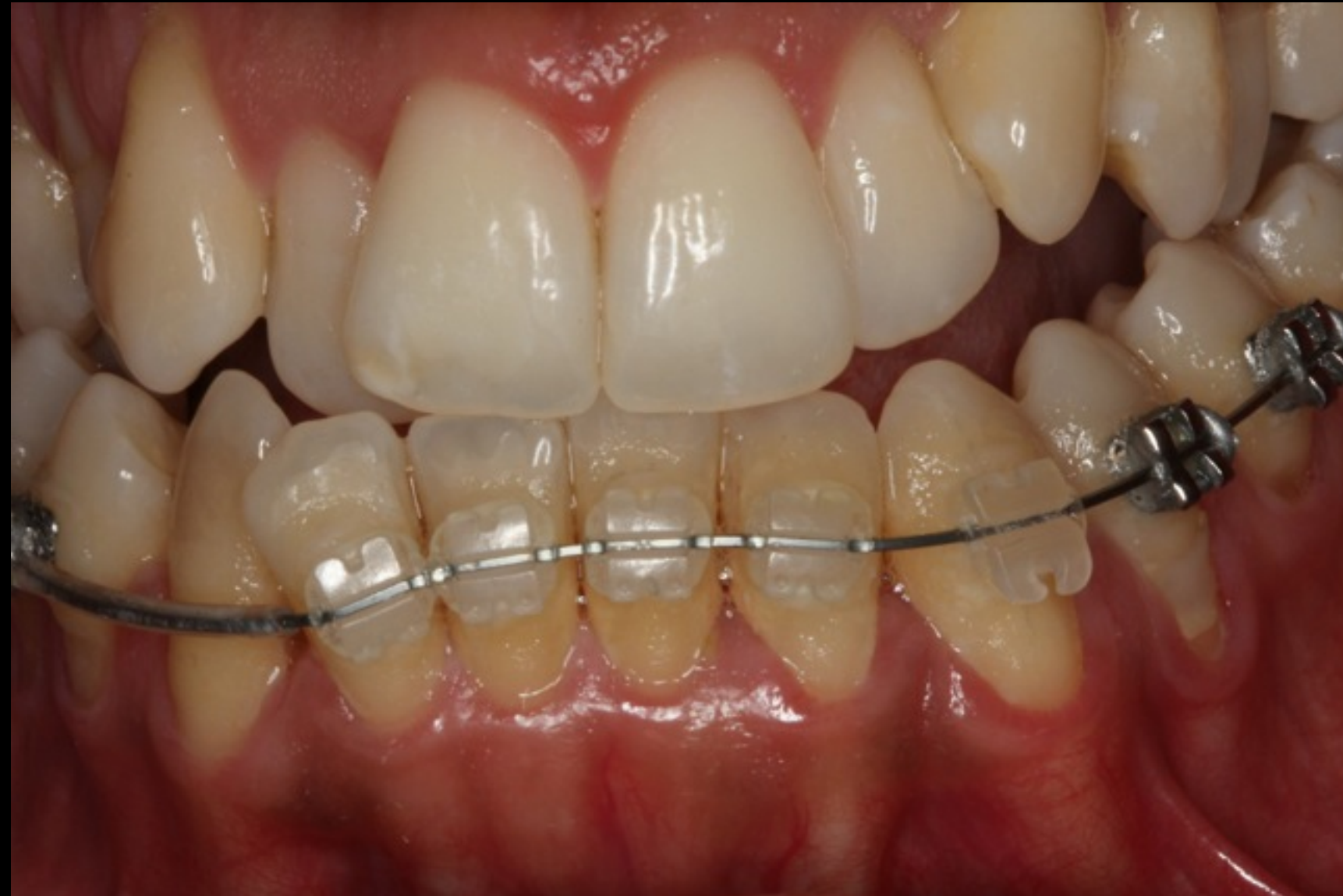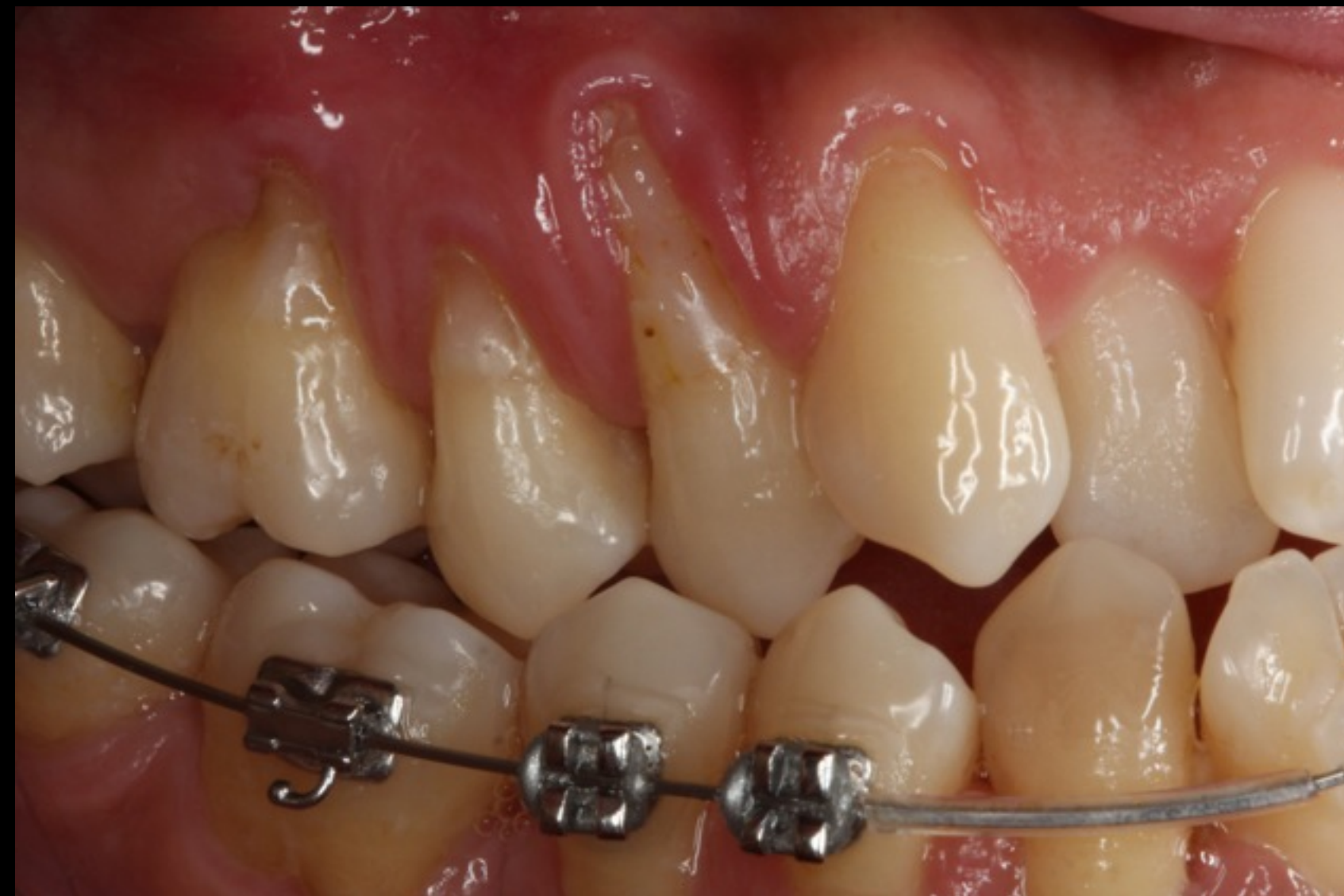Medical history: Unremarkable. NKDA

Current medications: None

Physical status classification: ASA I

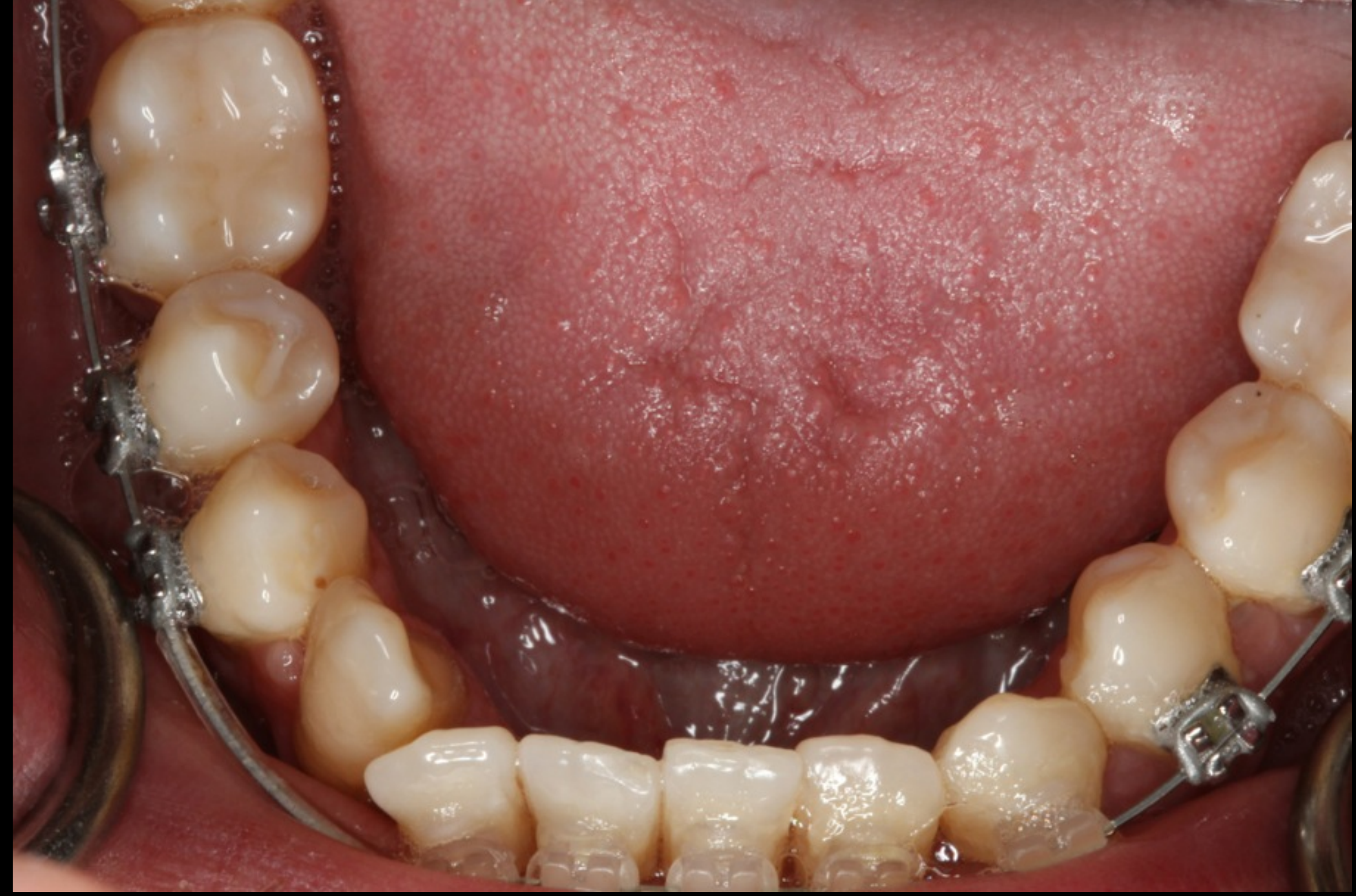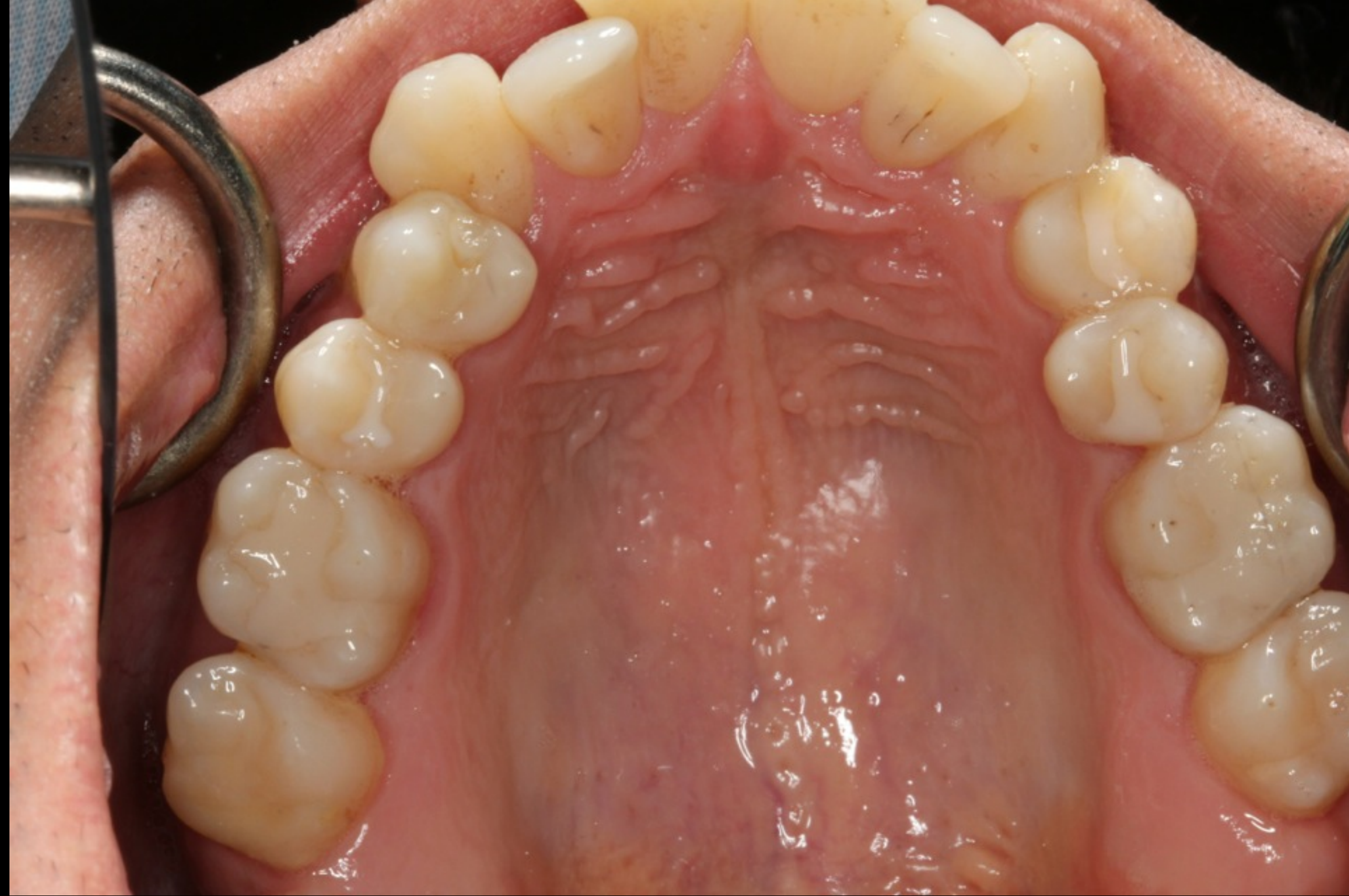Initial Exam

Angle Class III



Frontal & Buccal Views

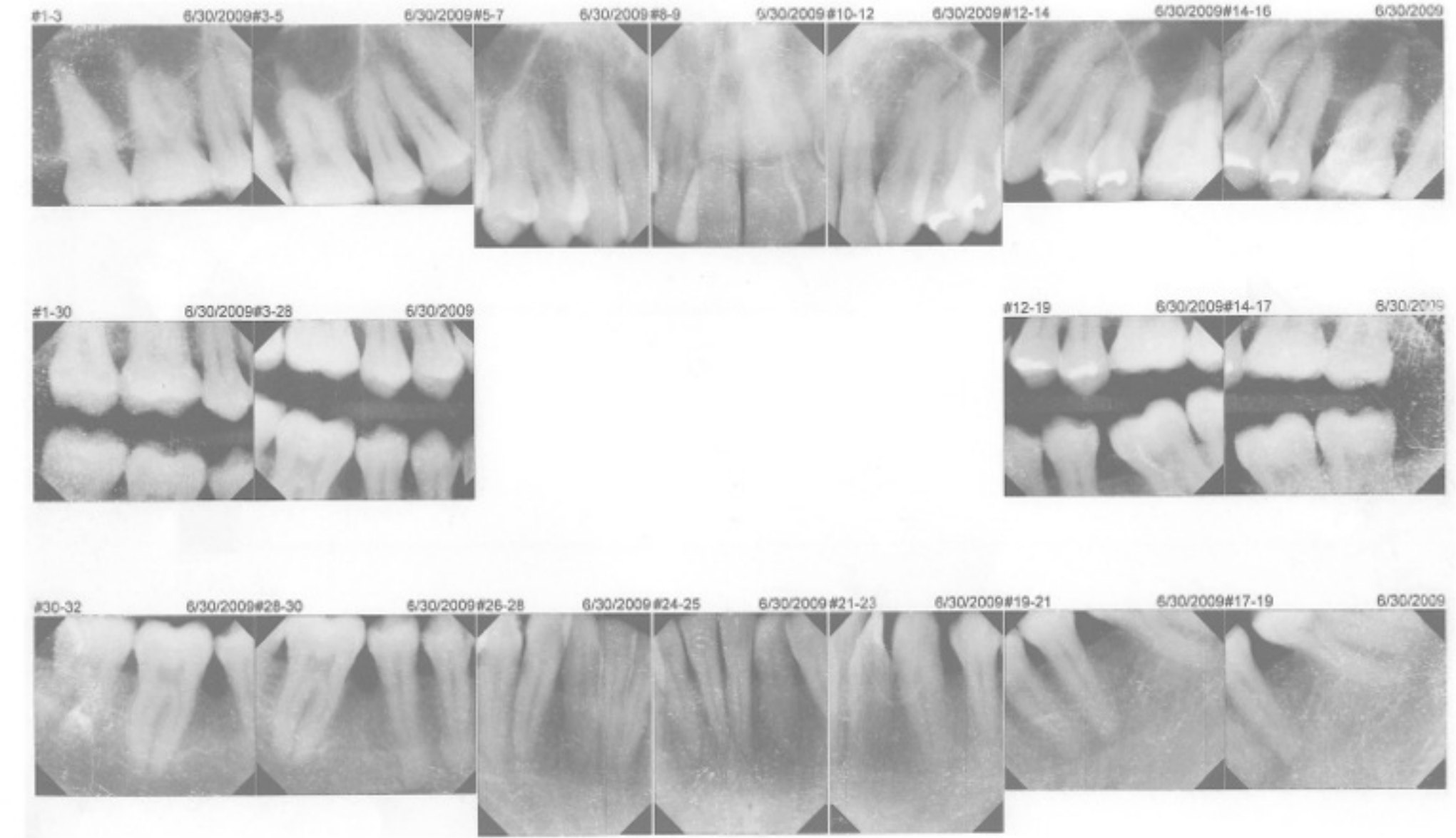
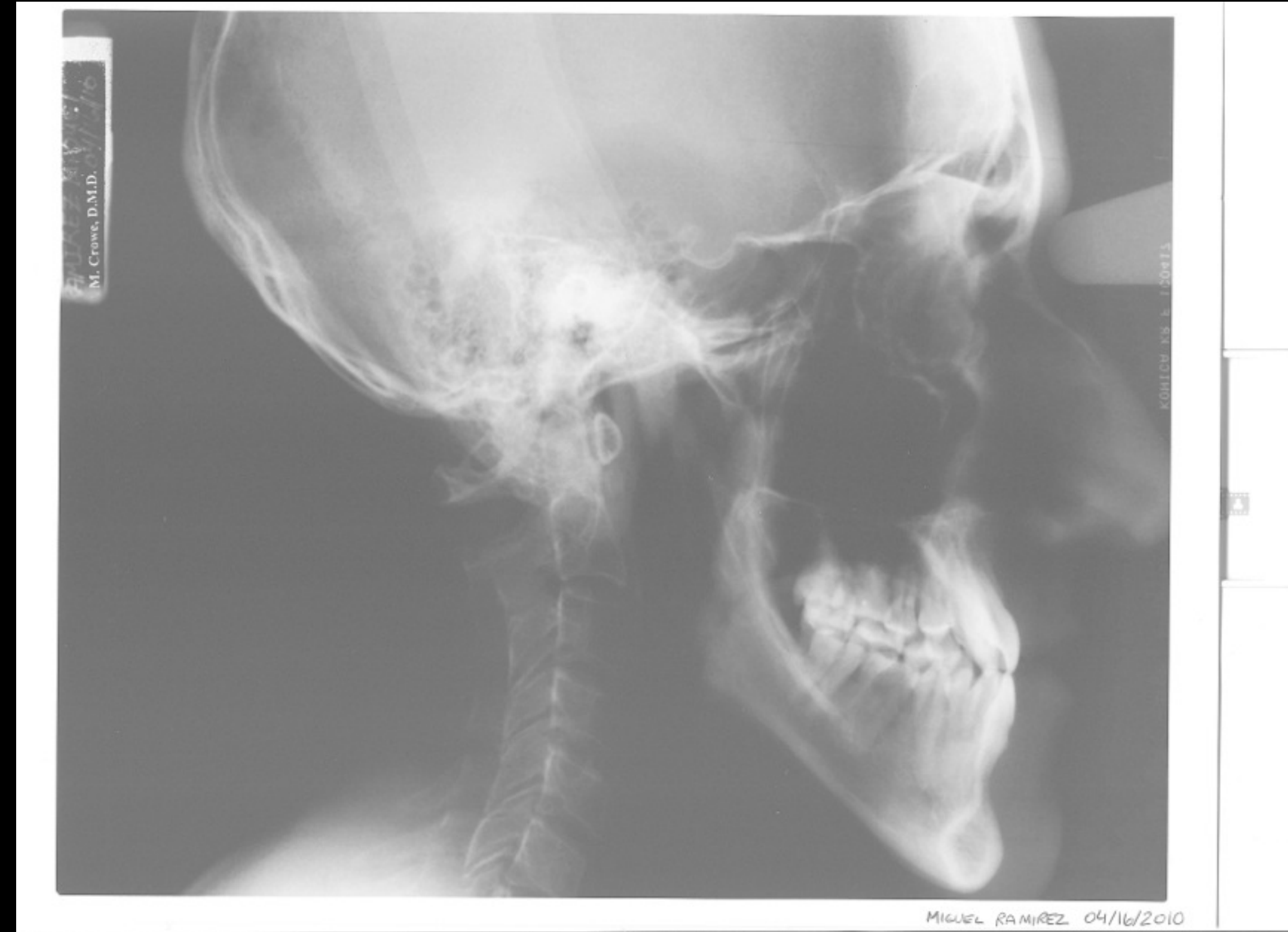Initial Exam



Occlusal views

Radiographs

Lateral Cephalometric



Full Mouth Radiographs

Typical Treatment Plan

"We can not solve problems by using the same kind of thinking we used when we created them"
Albert Einstein

Problem

Management

Dentoalveolar compensations



Orthodontic decompensation tooth movement

Skeletal malocclusion



Orthognathic surgery

**Assessment of Dentoalveolar bone?
Periodontal risk assessment?**



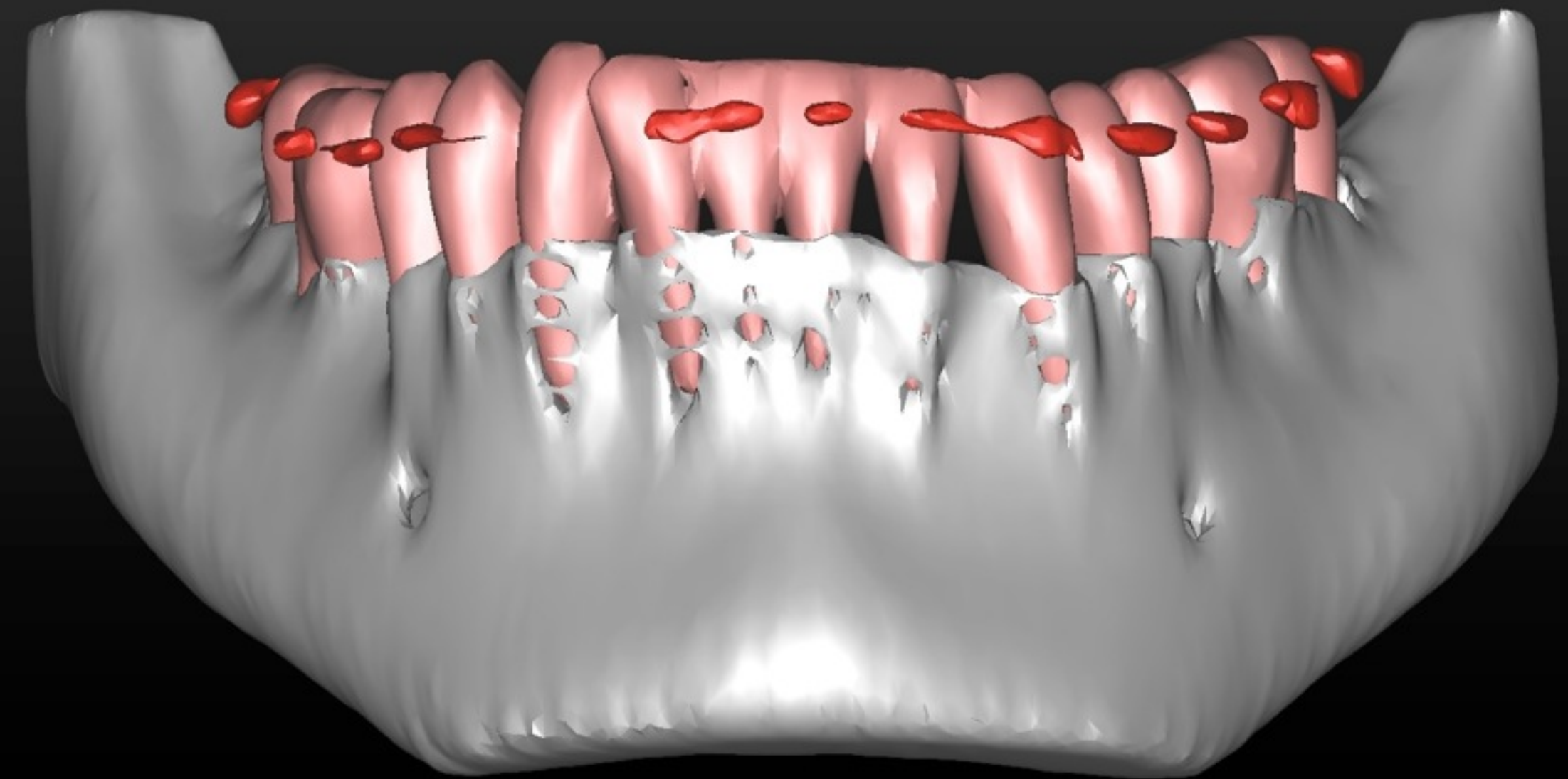
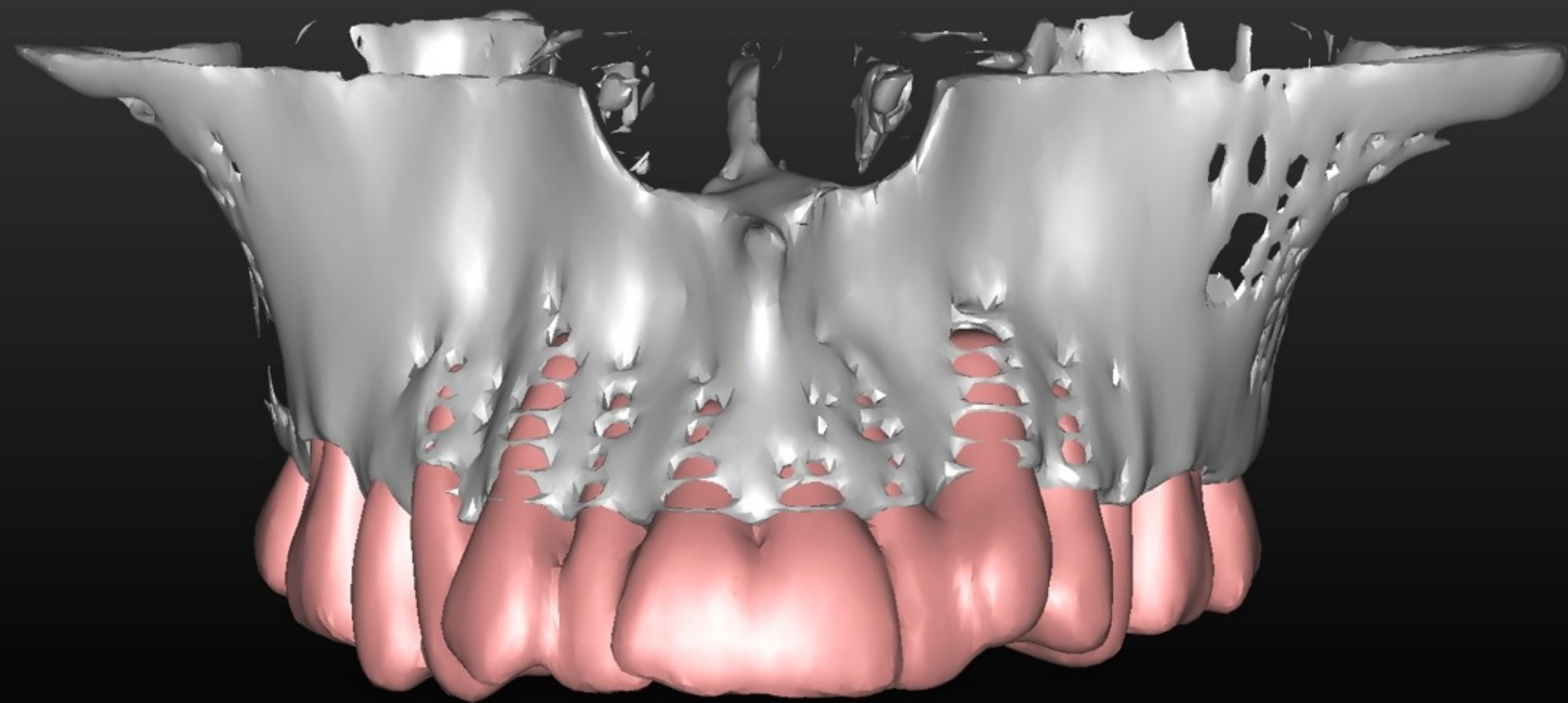
**Possible medicolegal related periodontal consultation to OK tooth movement.
Assessment of attached gingiva/recession & root coverage surgery AFTER orthognathics**

Skeletal Based Problems

Dentoalveolar & Alveoloskeletal

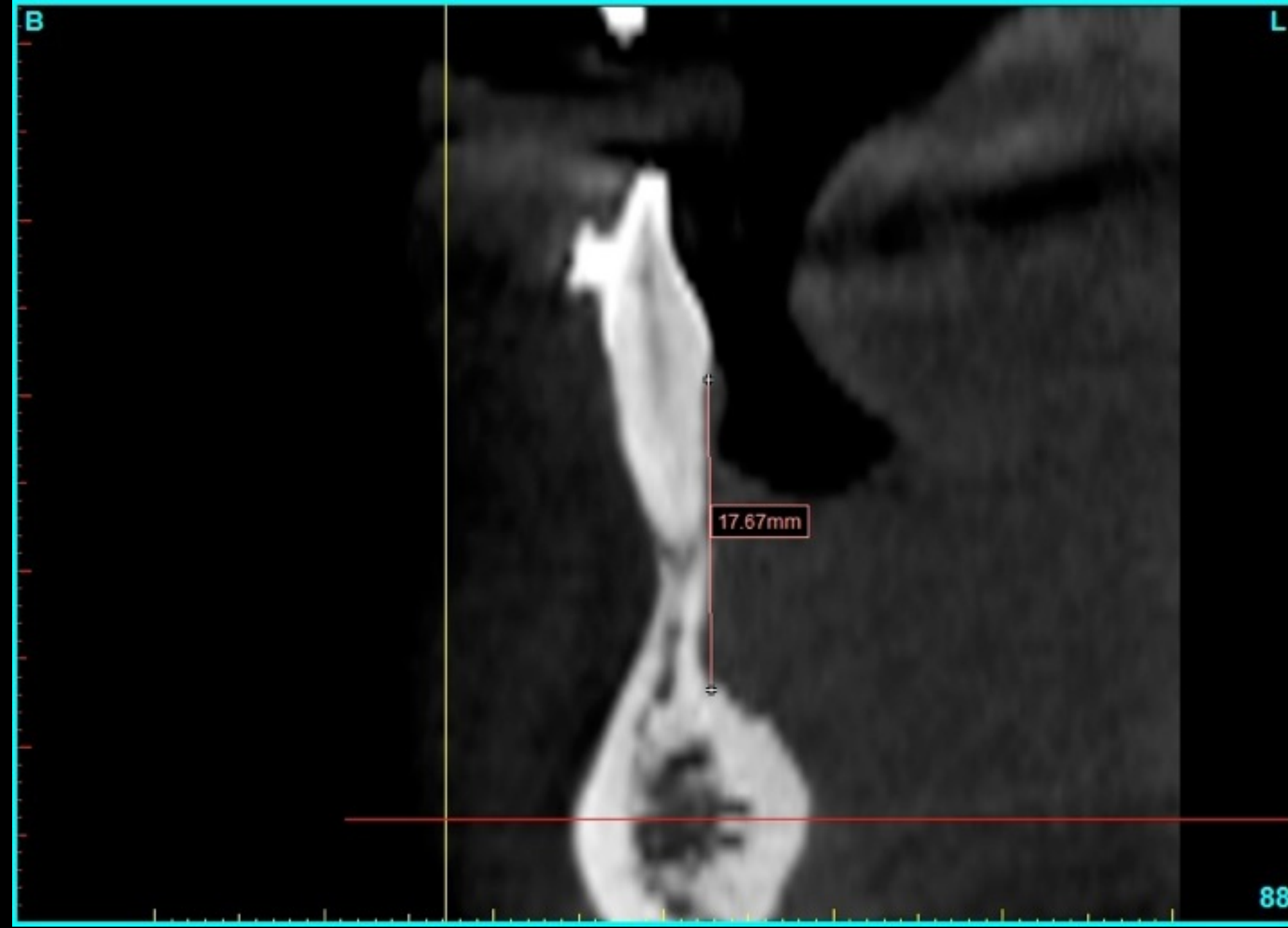Imaging

CBCCT Evaluation



3D assessment

Imaging

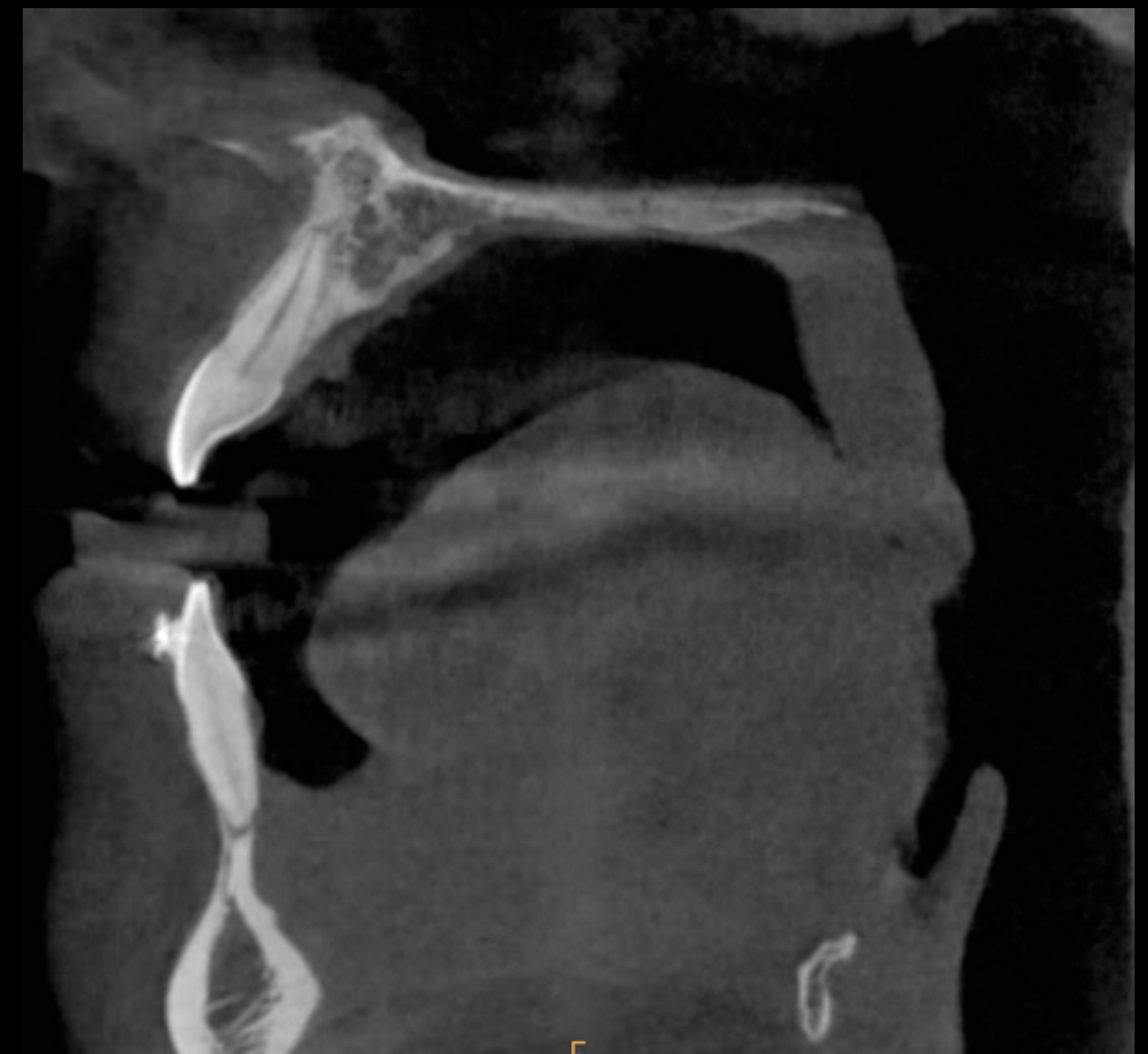

Myopic Imaging View

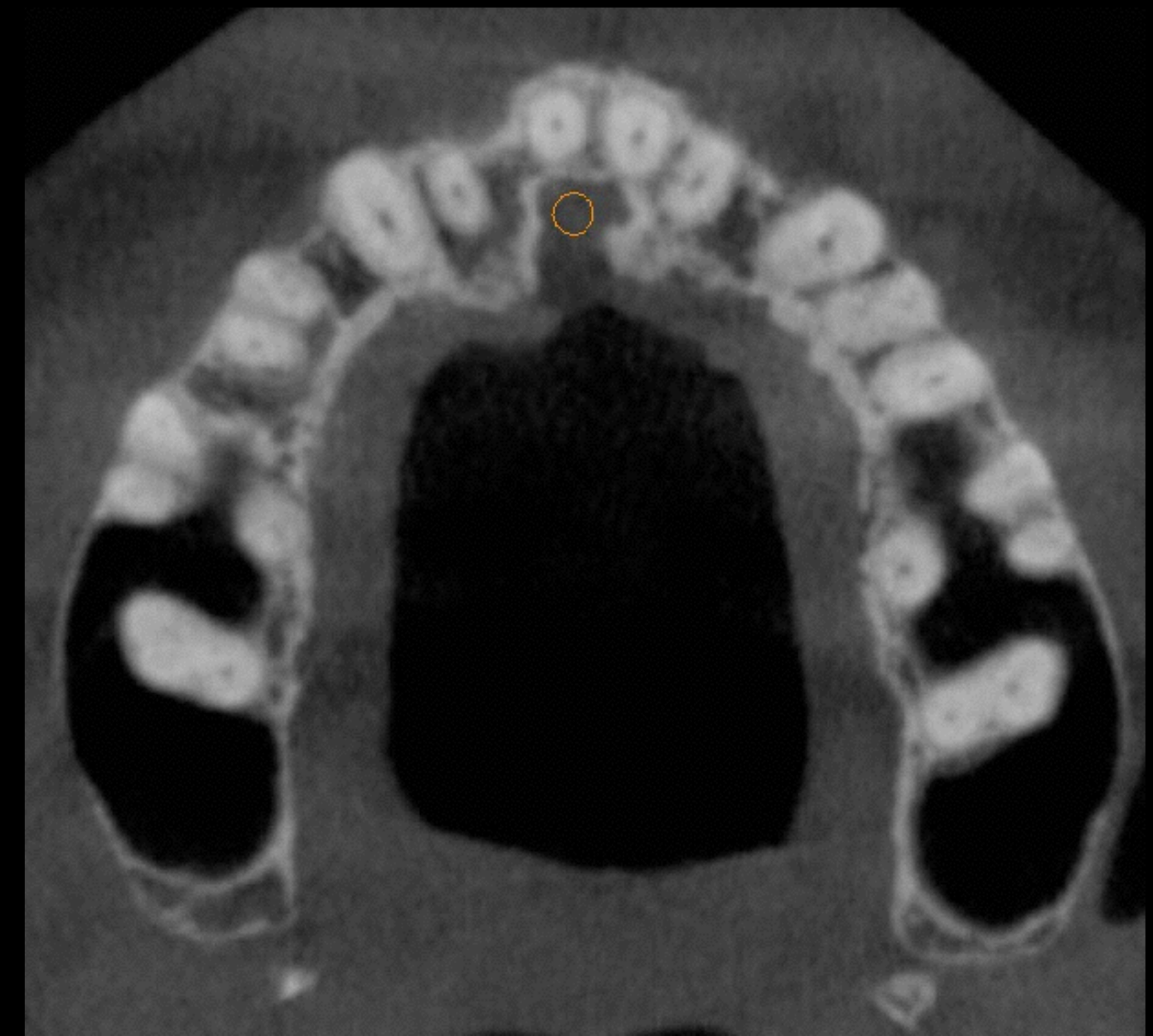
R I S K

Anterior Tooth Relationship

Imaging. Pre Op



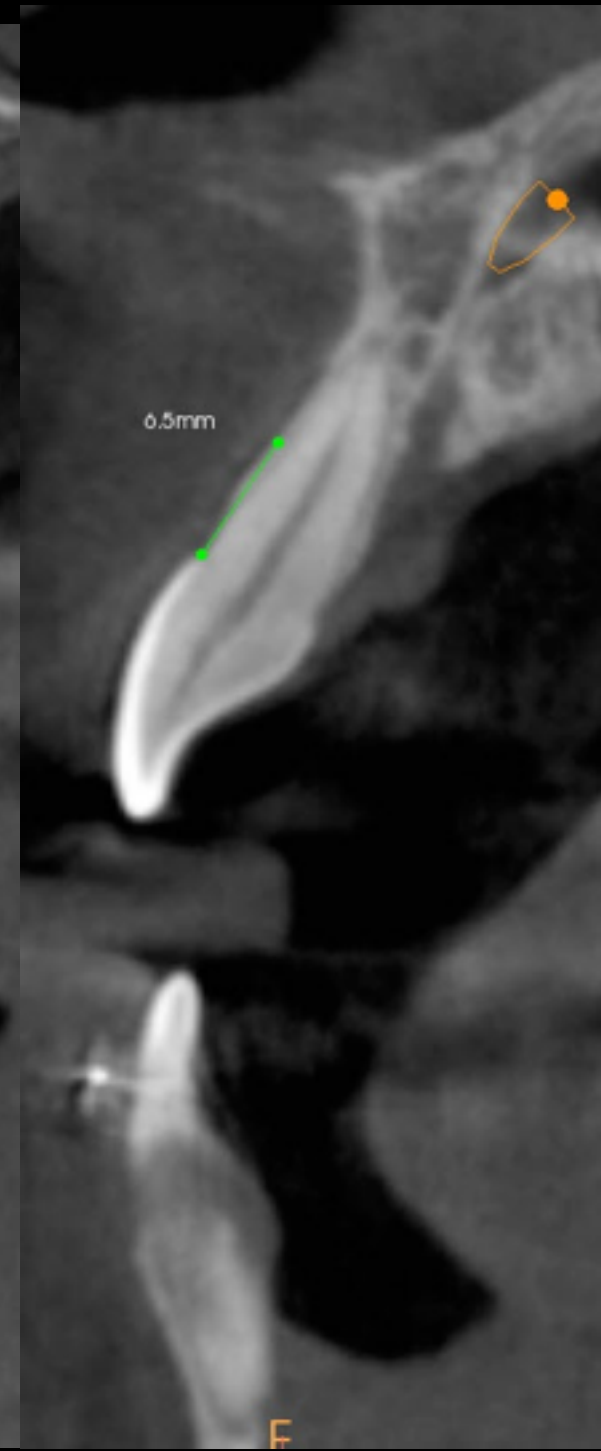
Sagittal



Axial




5



Cross sectional

9



14

Axial and Cross Sectionals

SFOT Treatment Plan

Problem

Gingival recession

Management

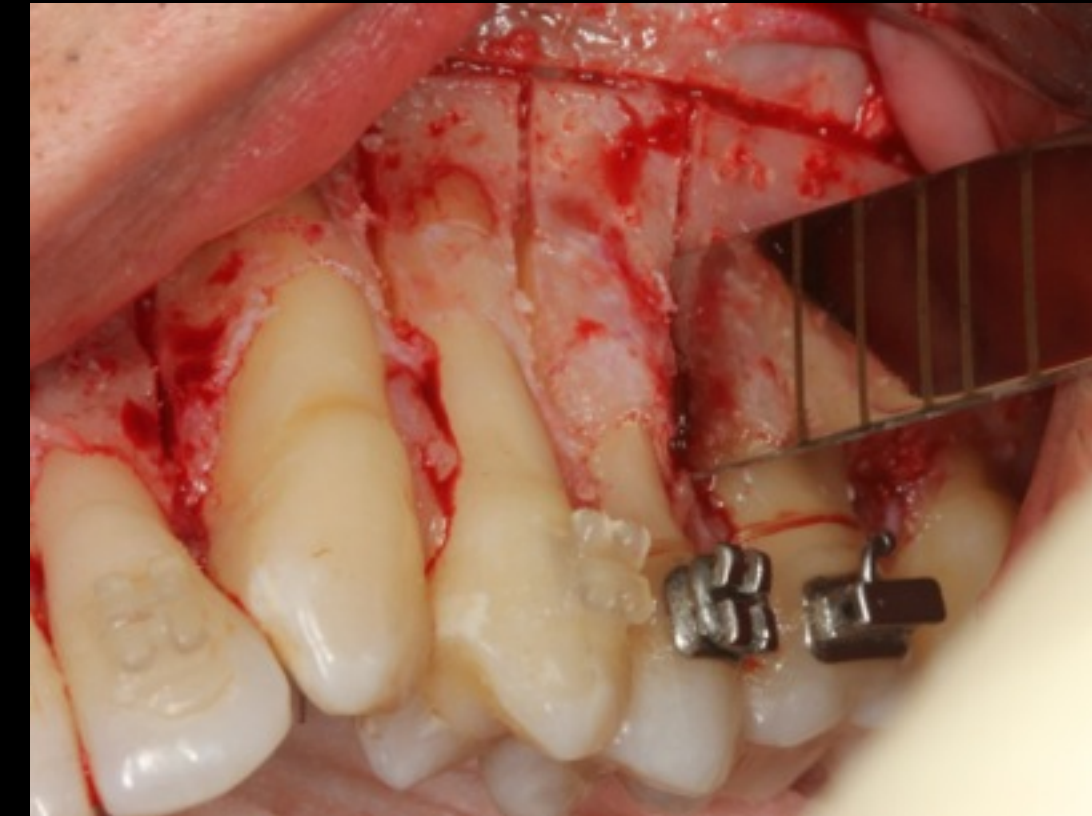
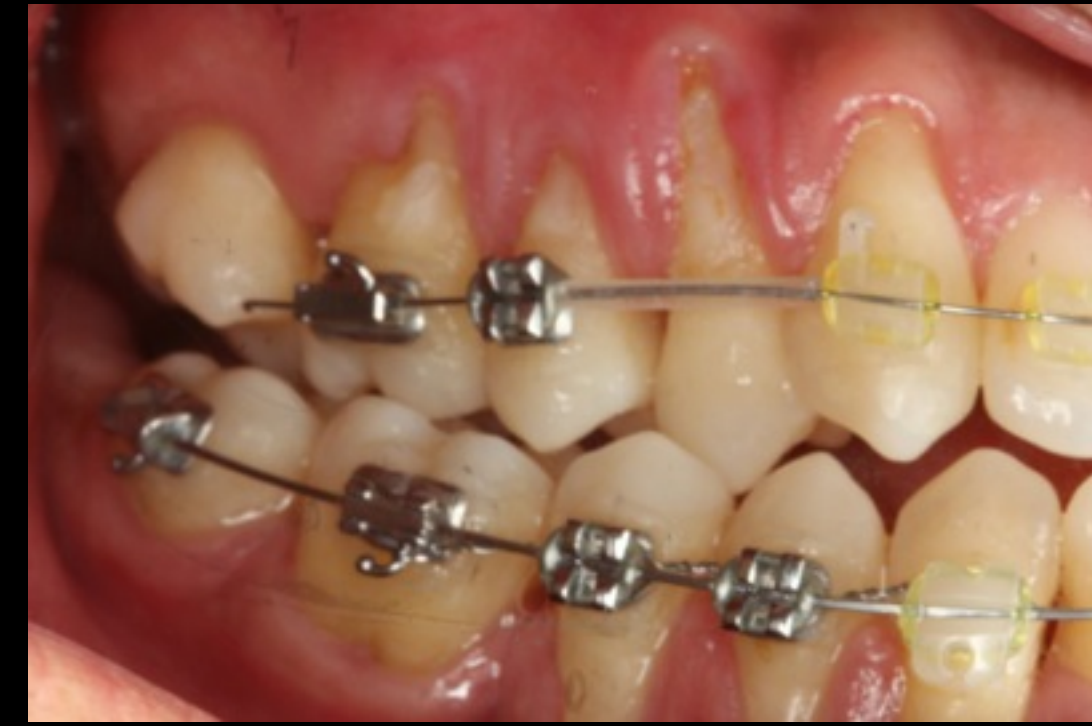Connective Tissue Grafting

Dentoalveolar Bone Deficiency
Alveoloskeletal Bone Deficiency

S F O T

Skeletal malocclusion

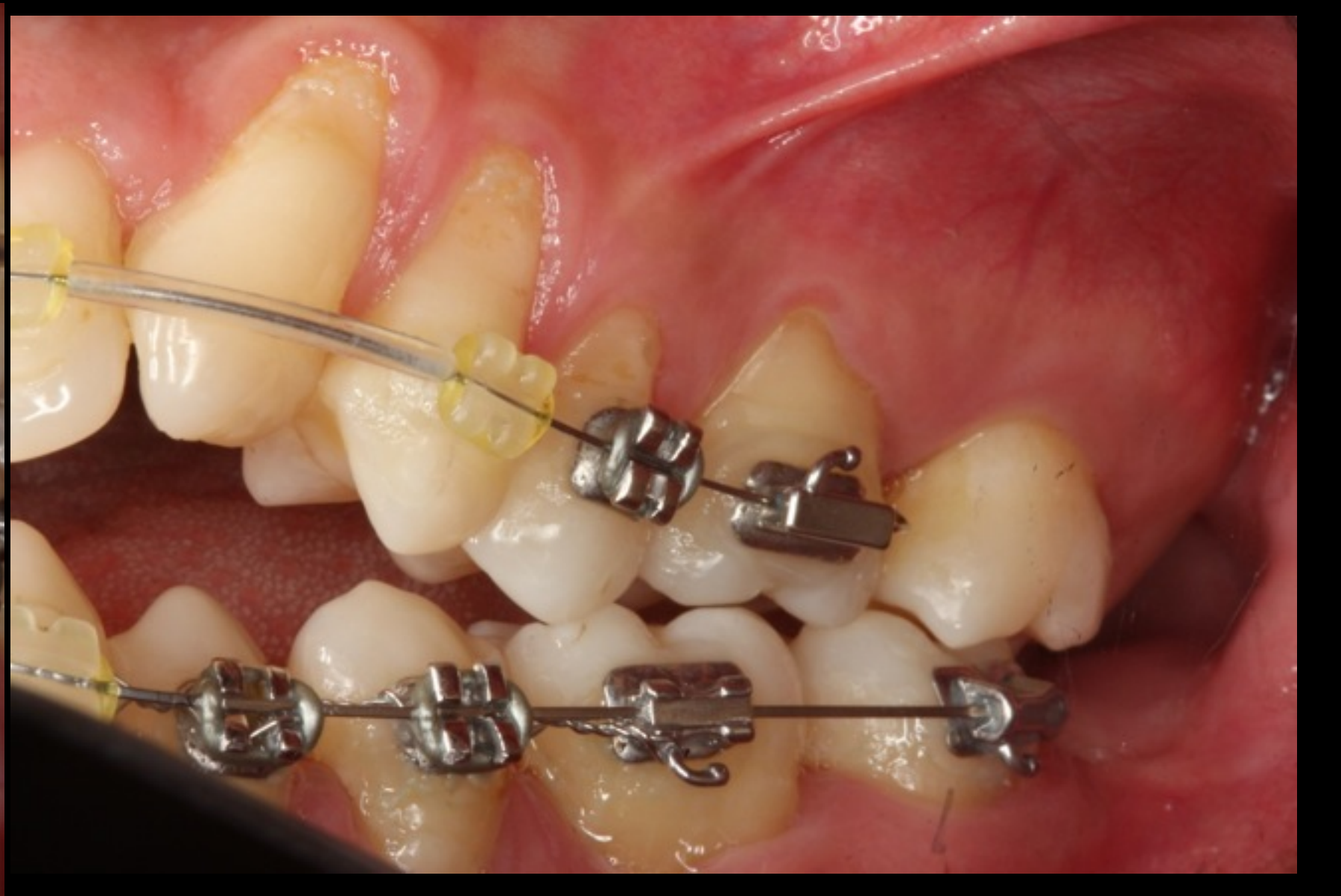
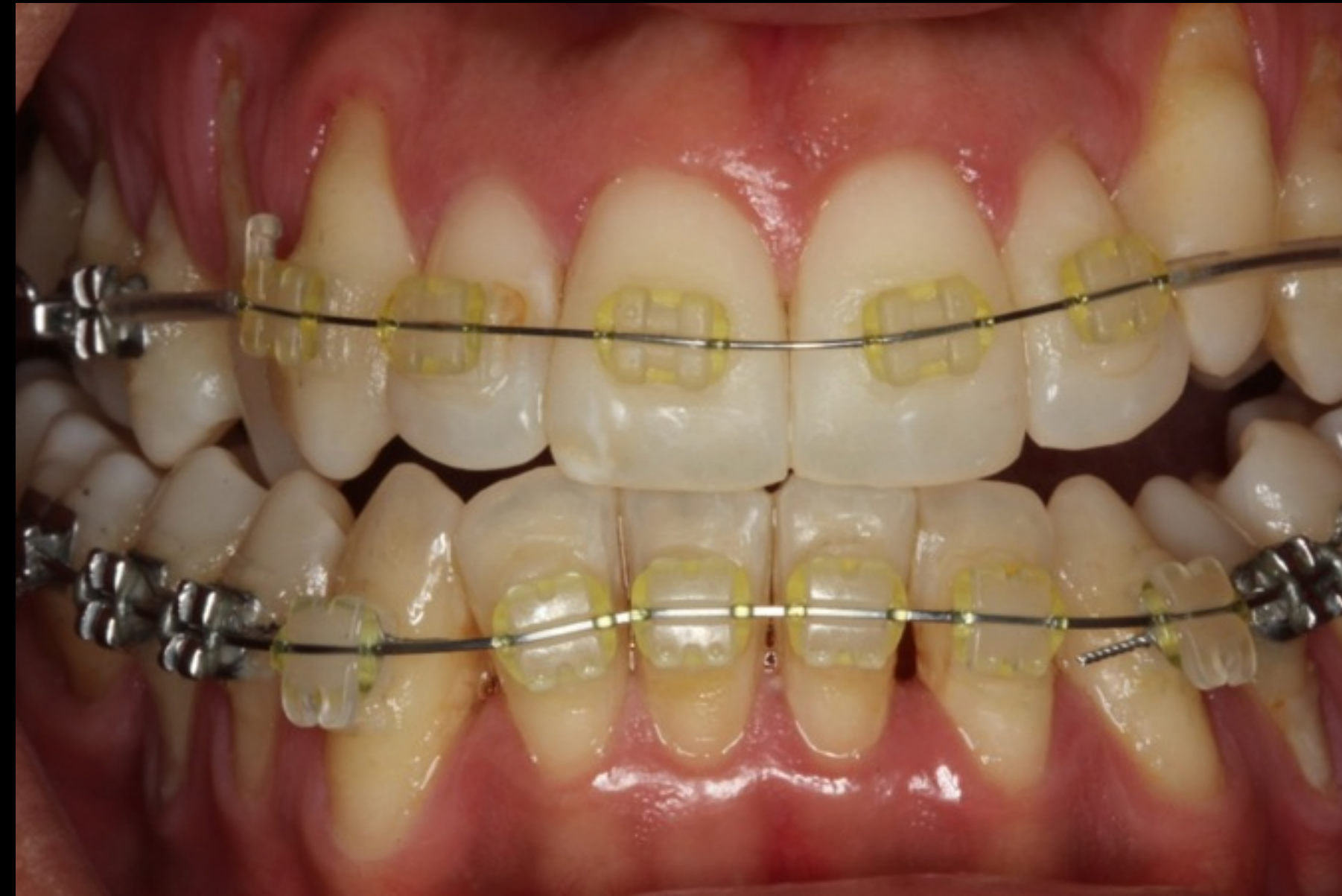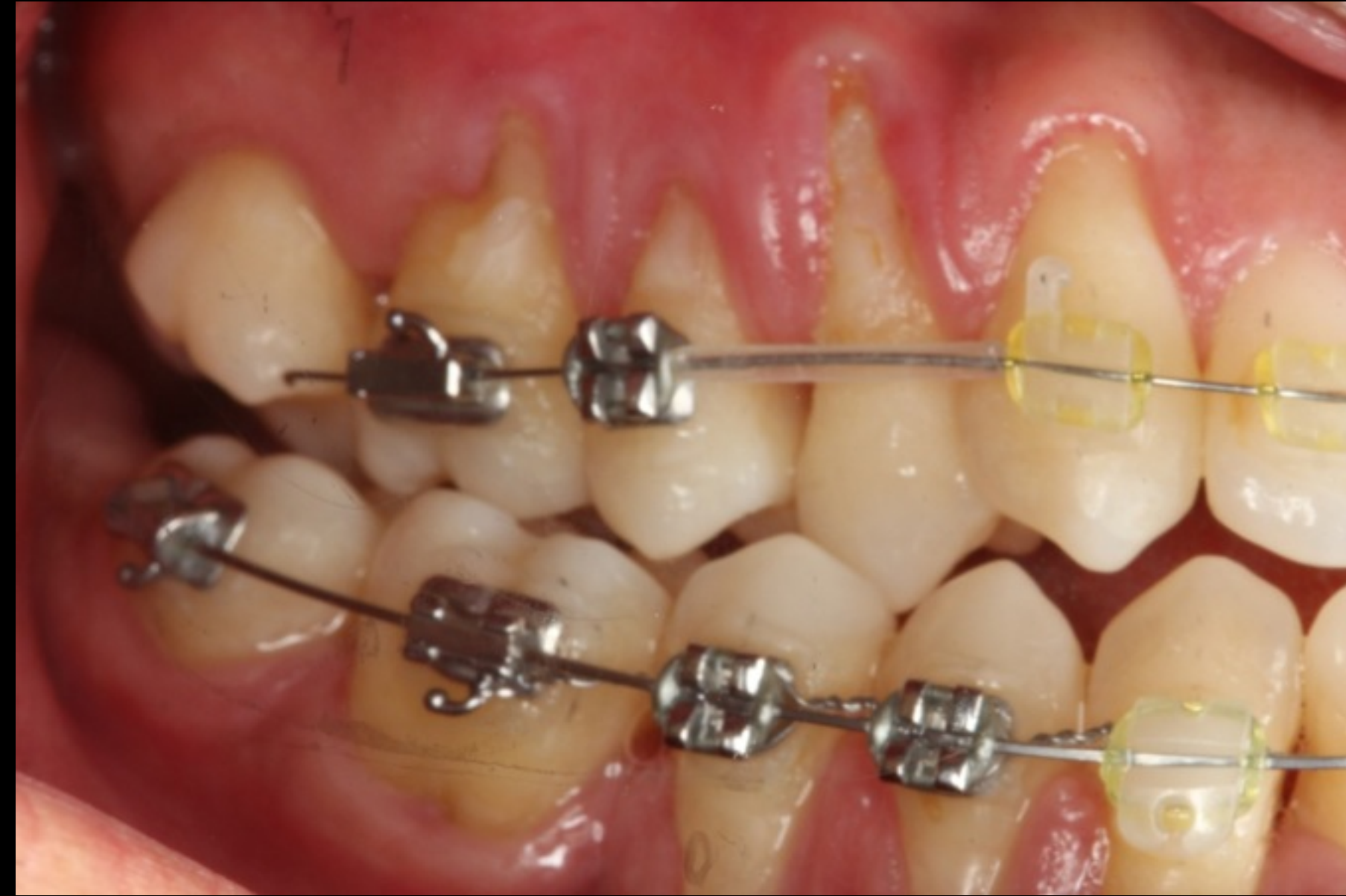
Orthognathic Surgery



??????????

Re - evaluating Solutions for the Problem

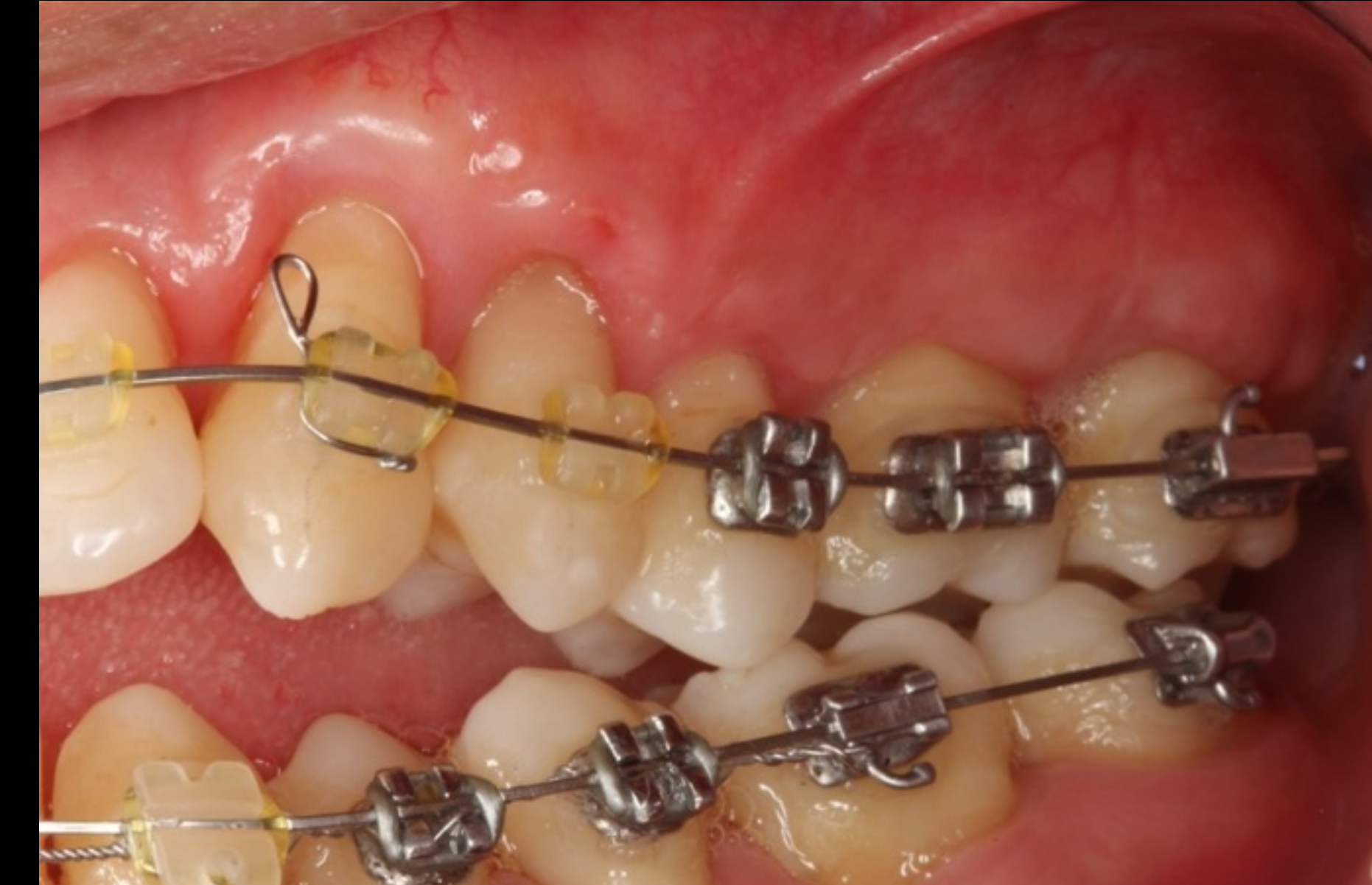
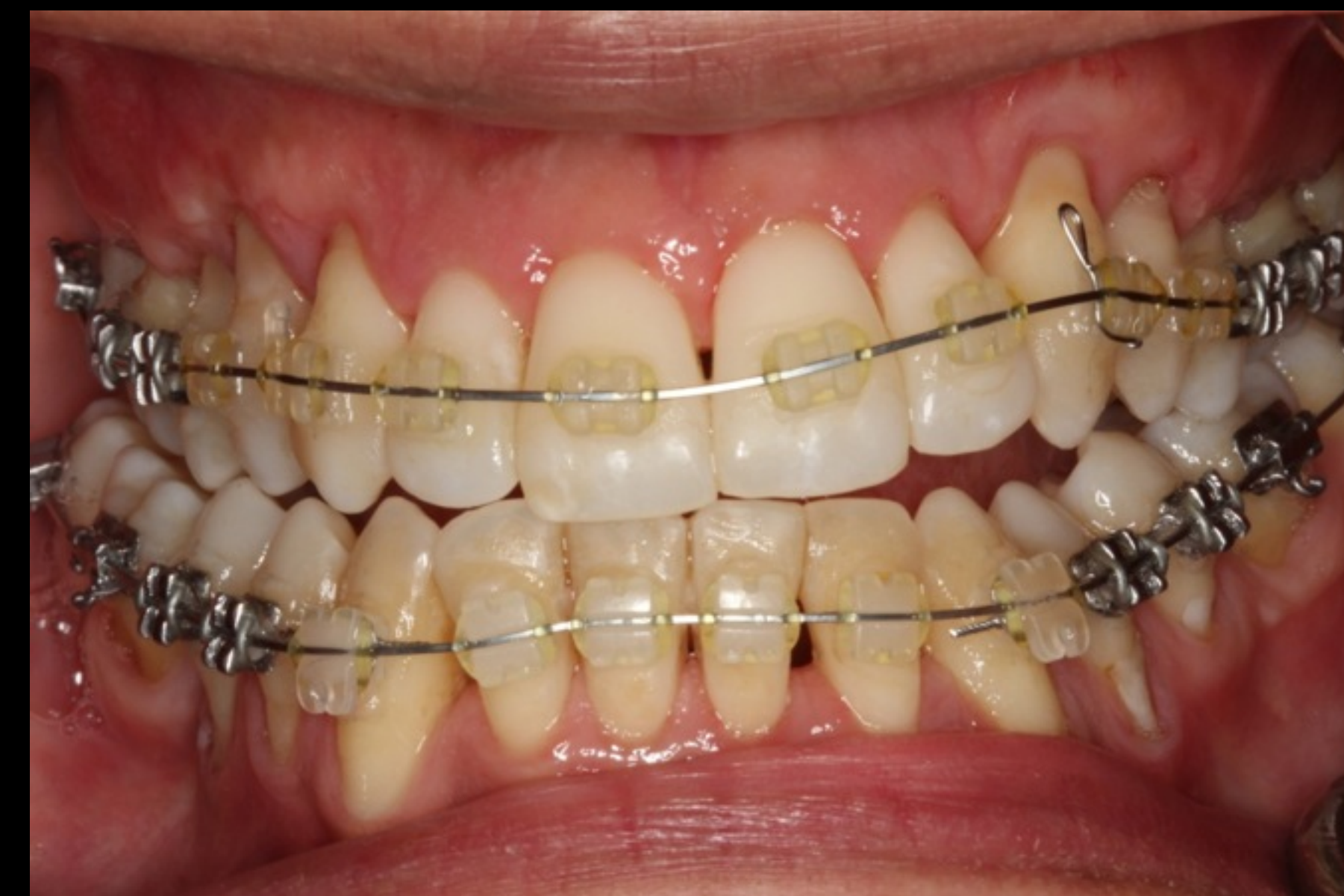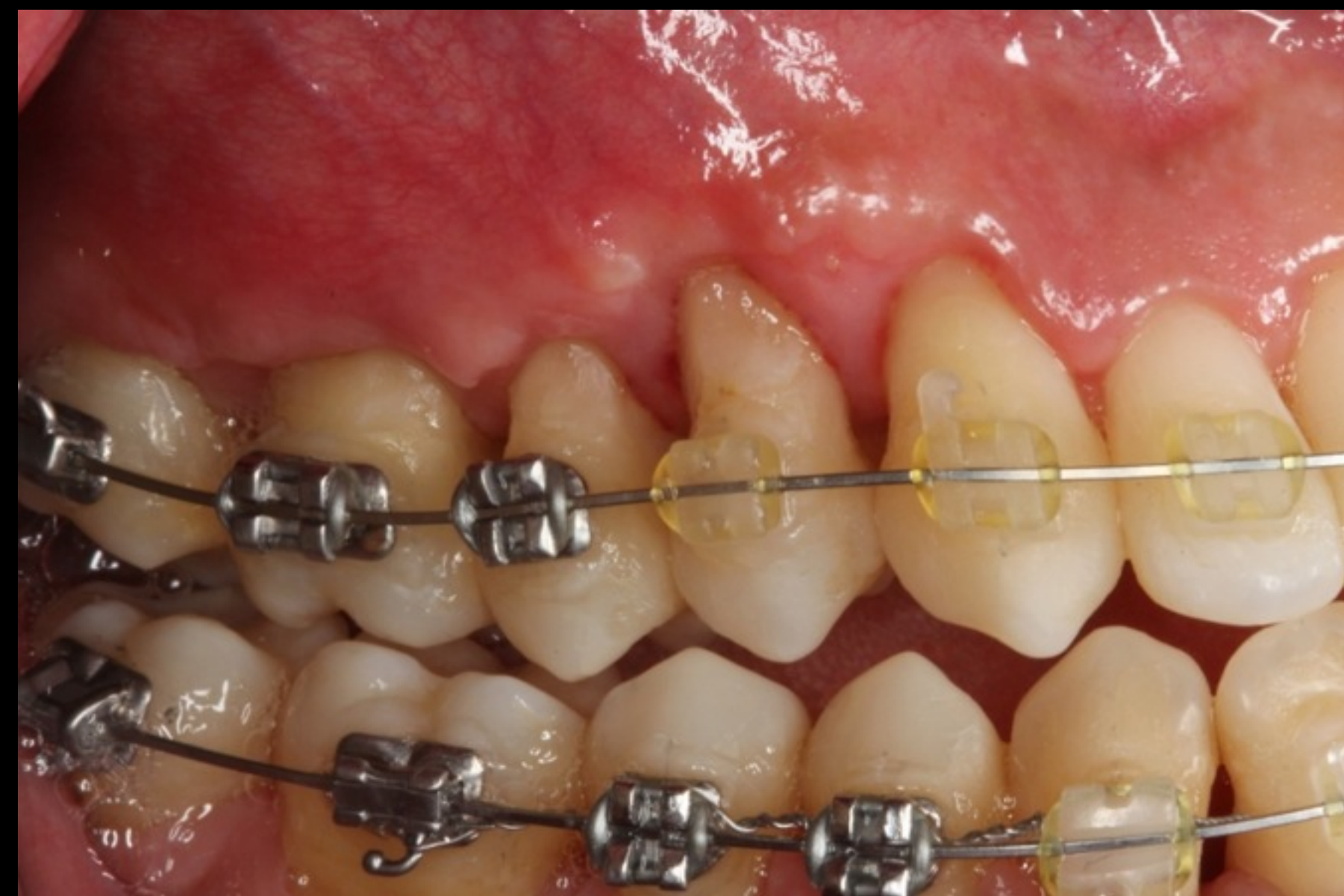Changing Paradigms



Re-evaluating risk

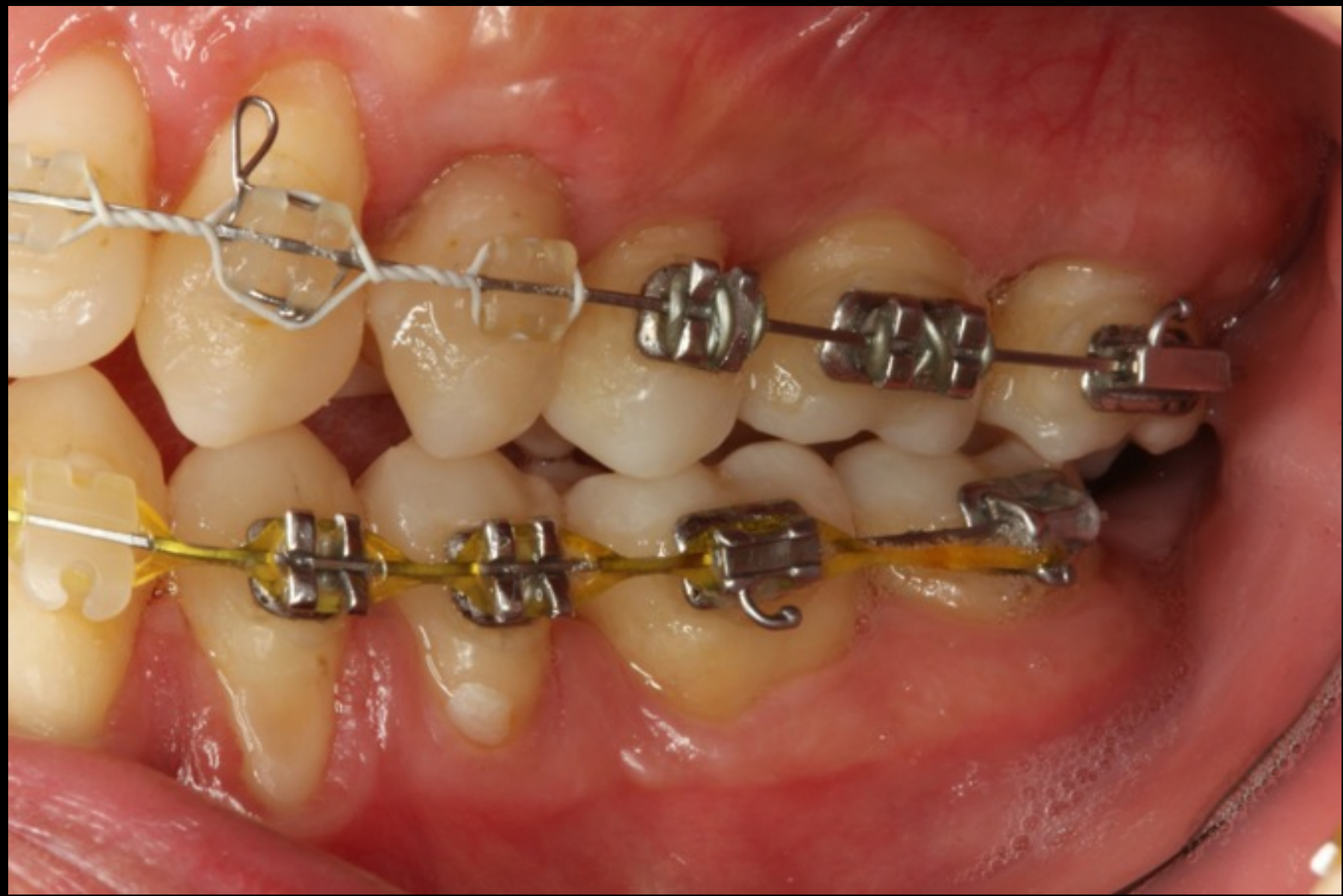
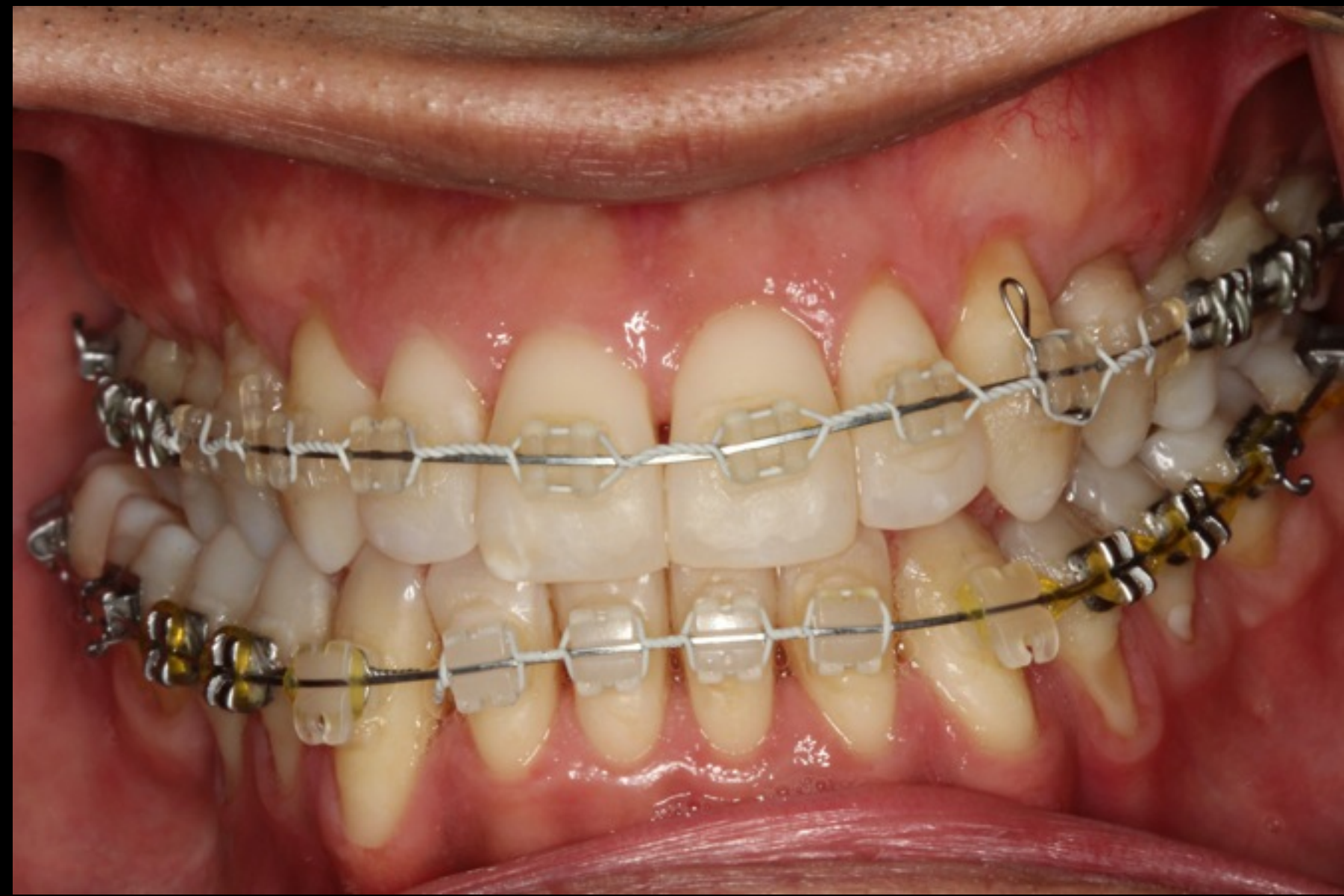
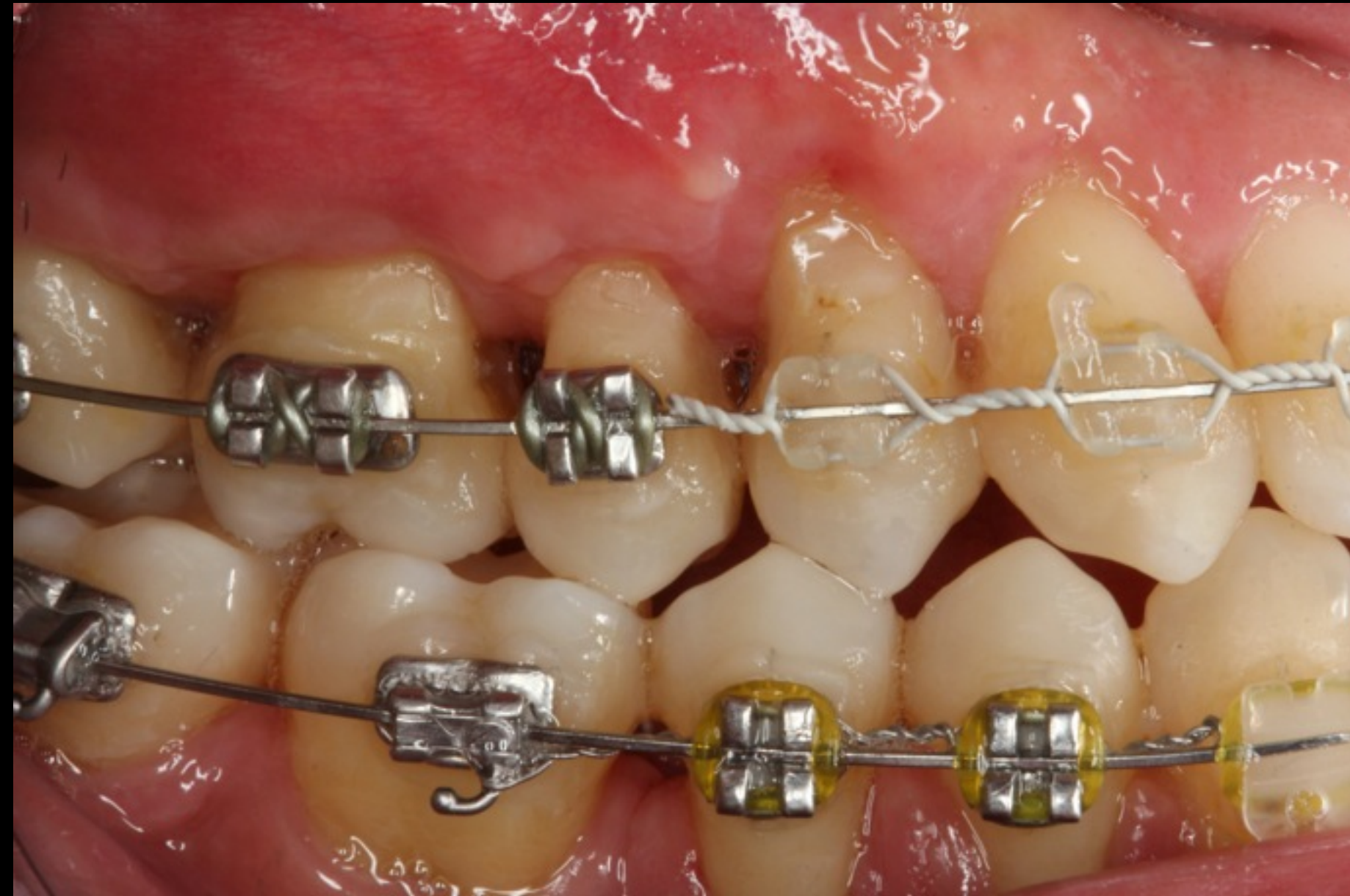
Healing assessment

8 week post op



2 months post op

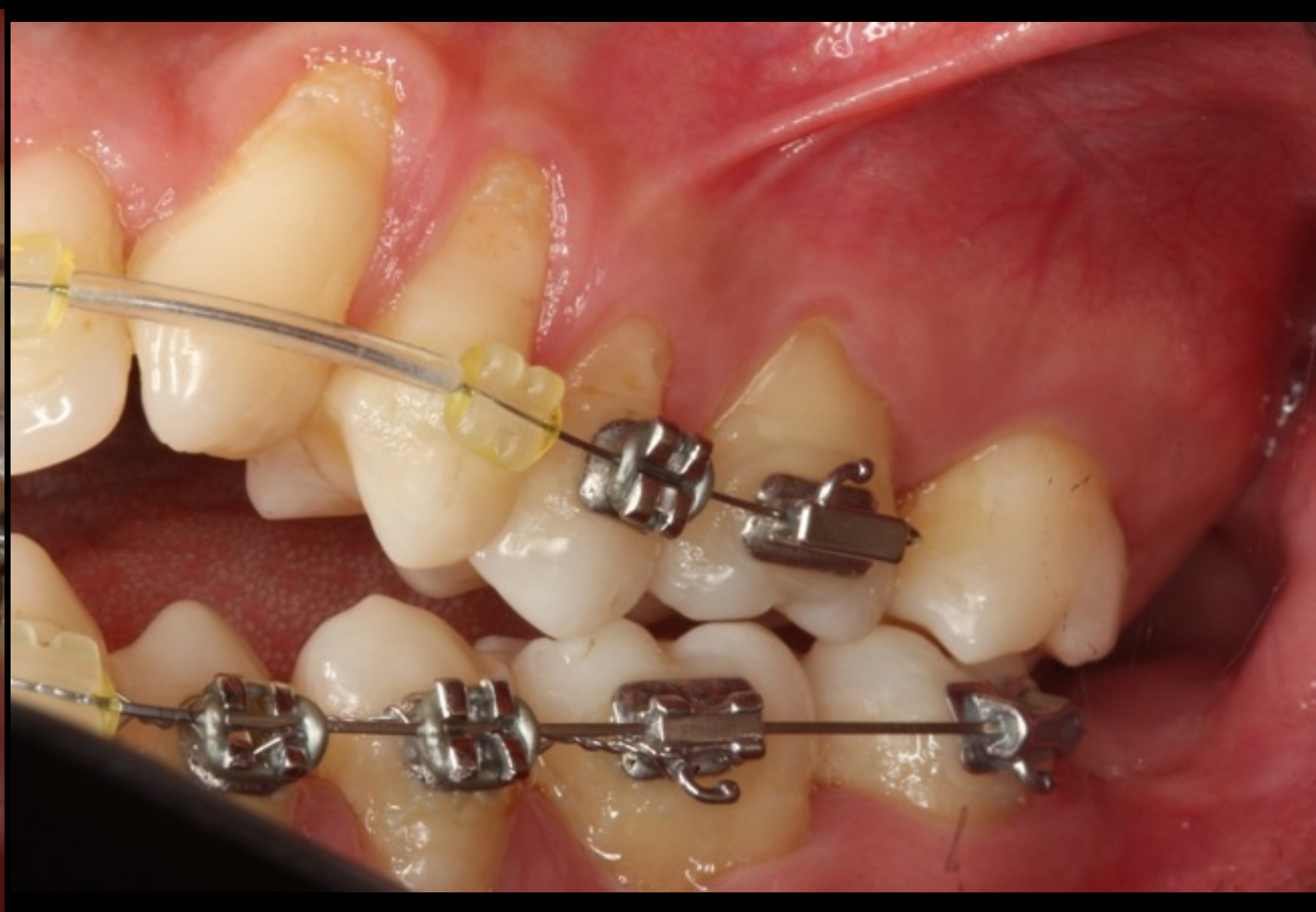
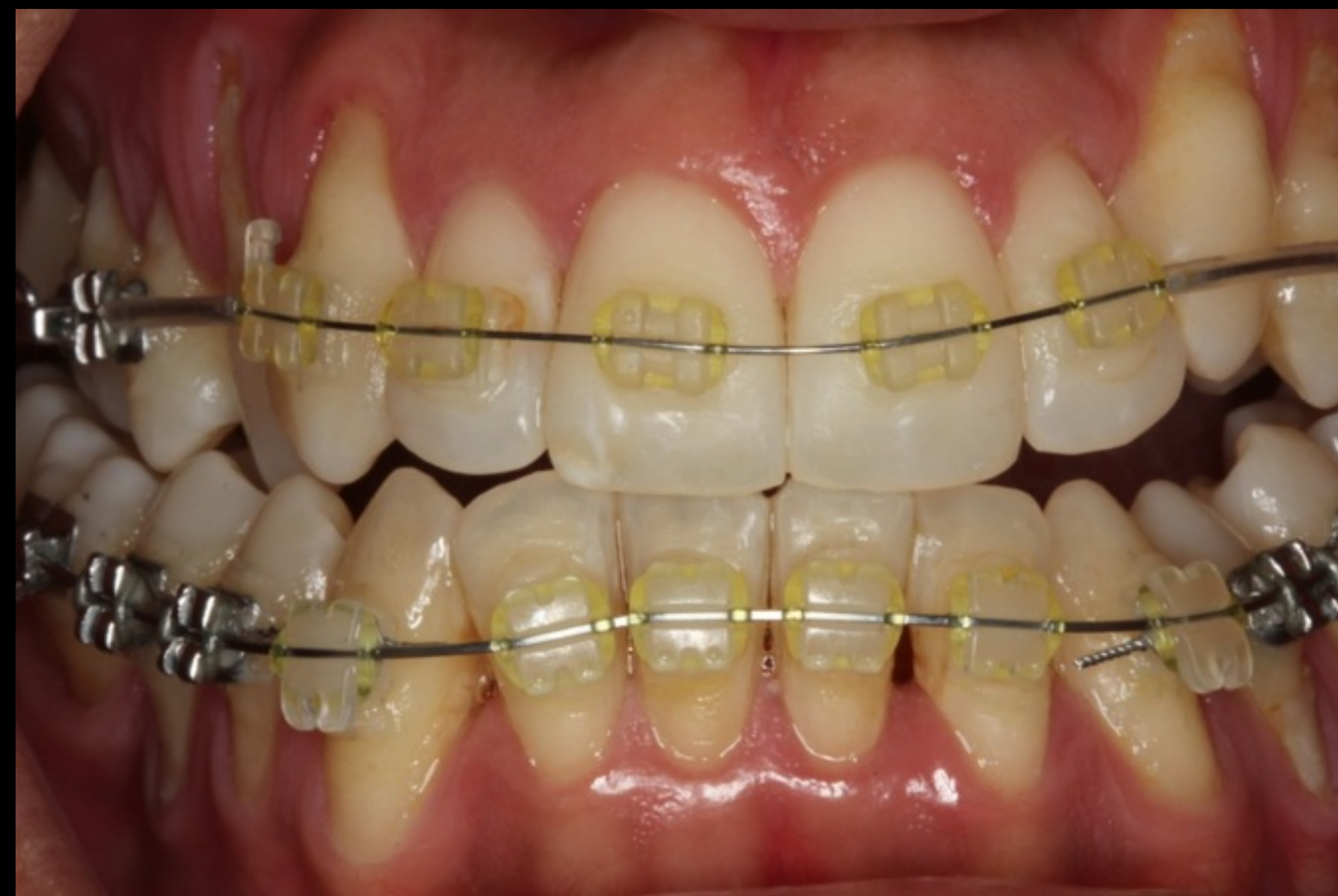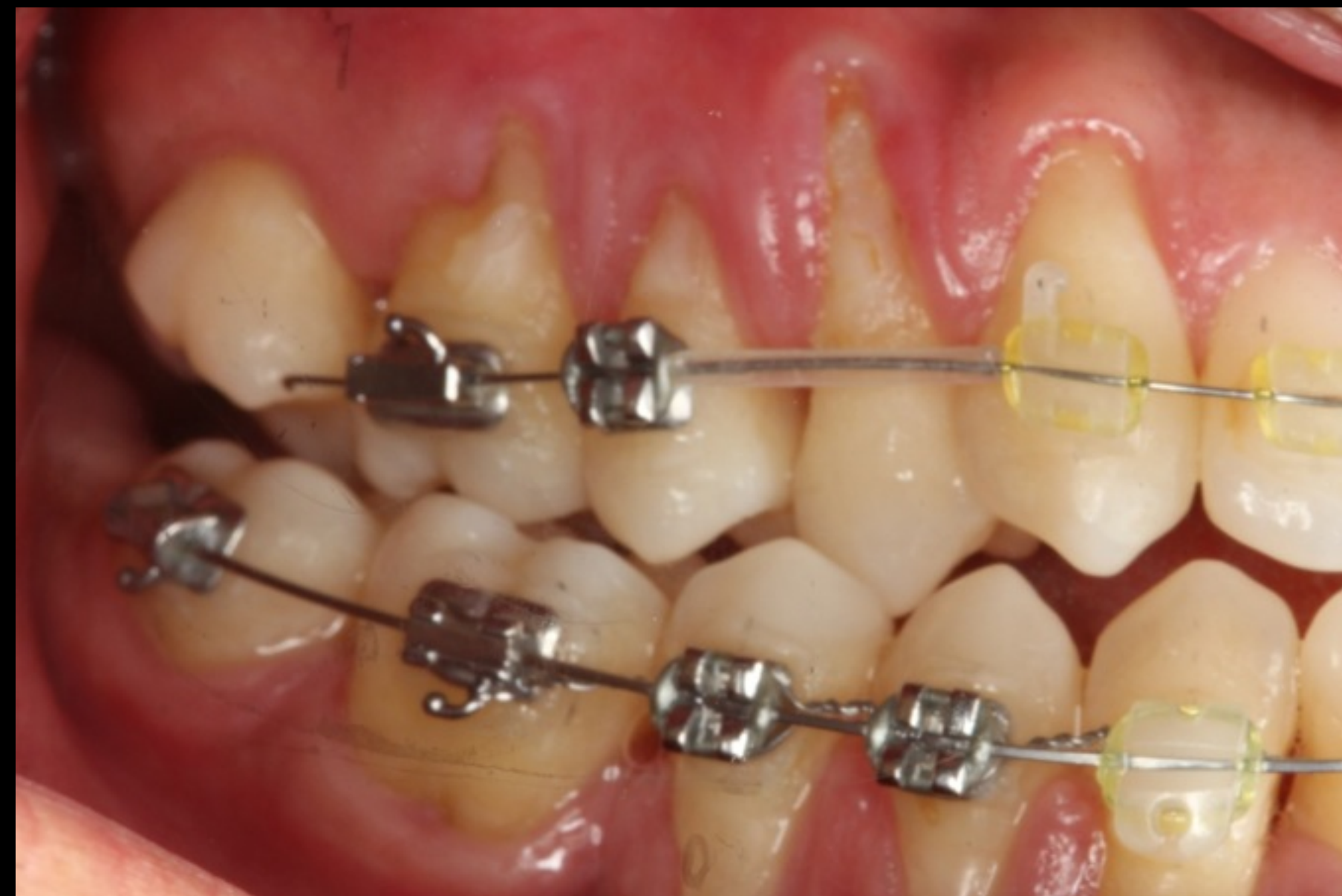10 months post op



10 month post op

Re - evaluating solutions for the problem

Phenotype Transformation

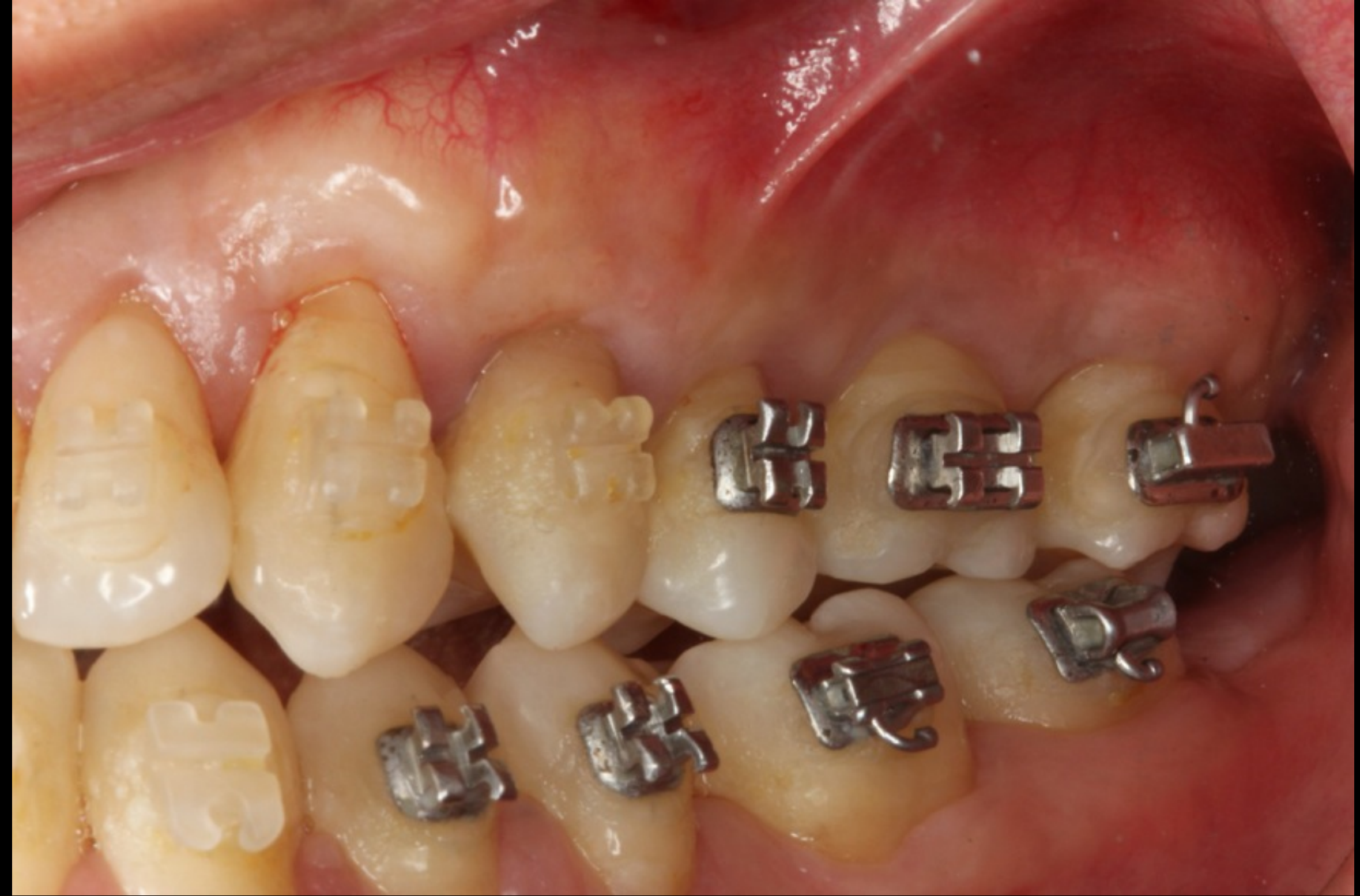
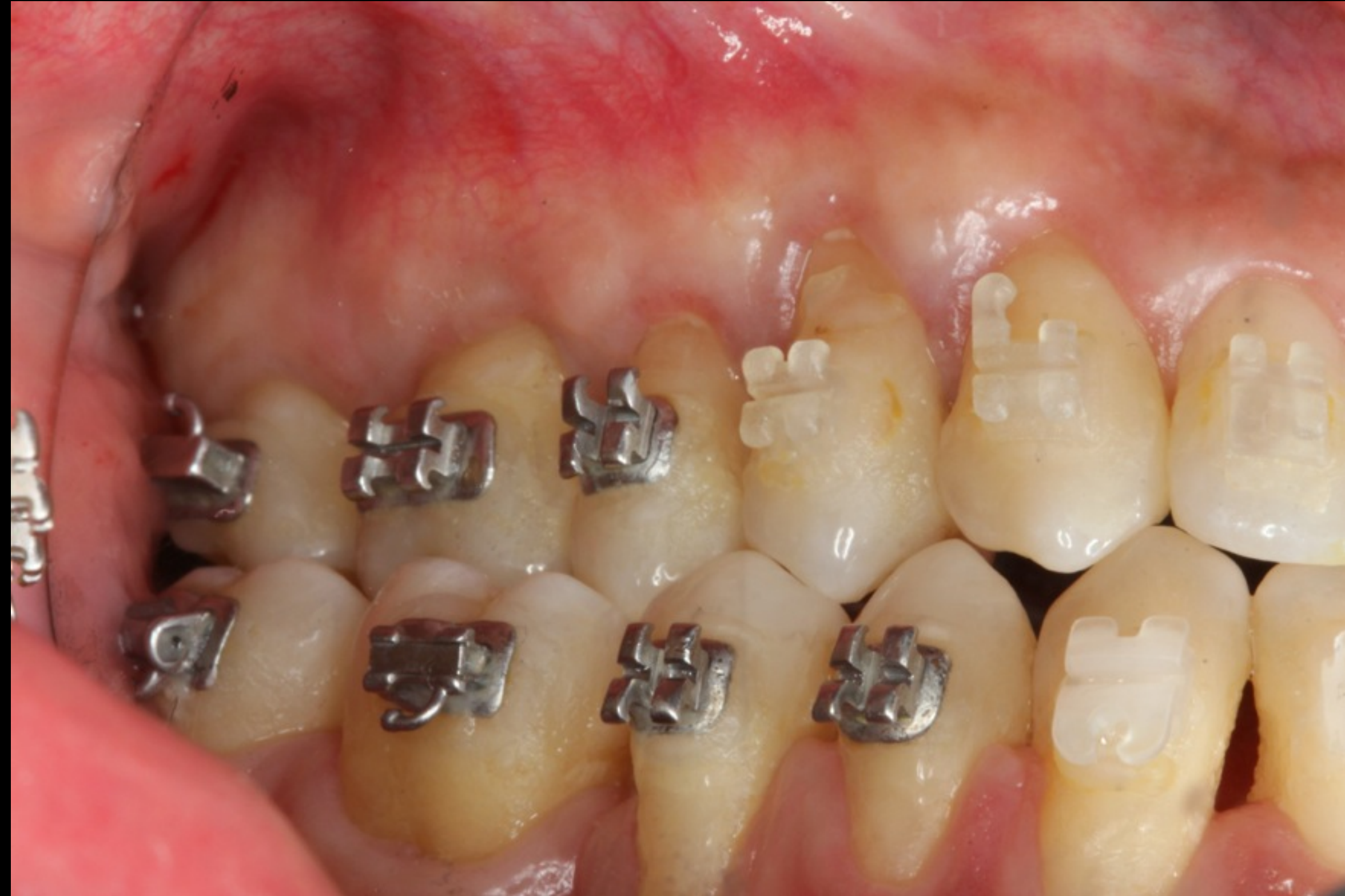
Re-evaluating risk

Initial Exam

Follow Up

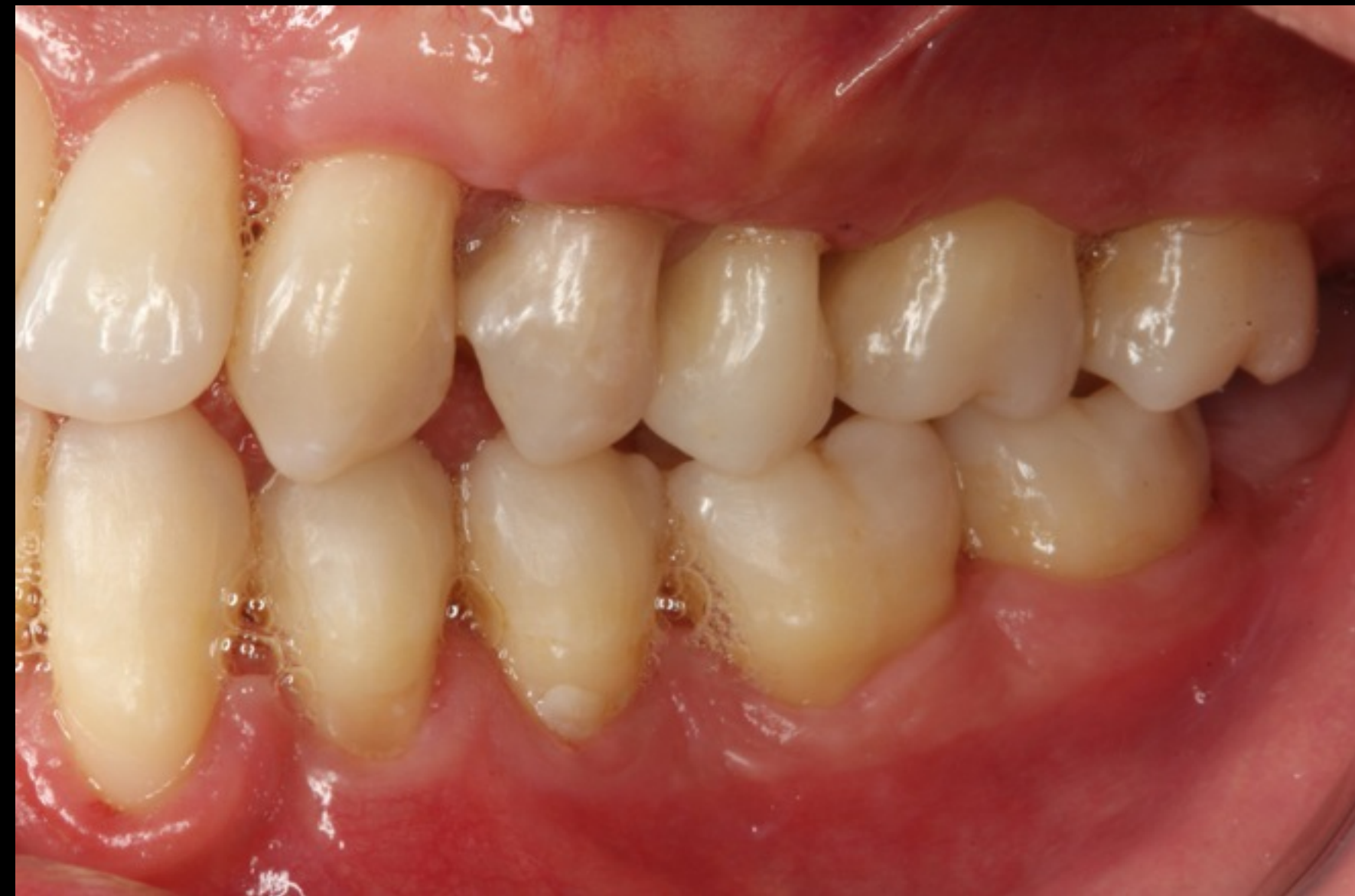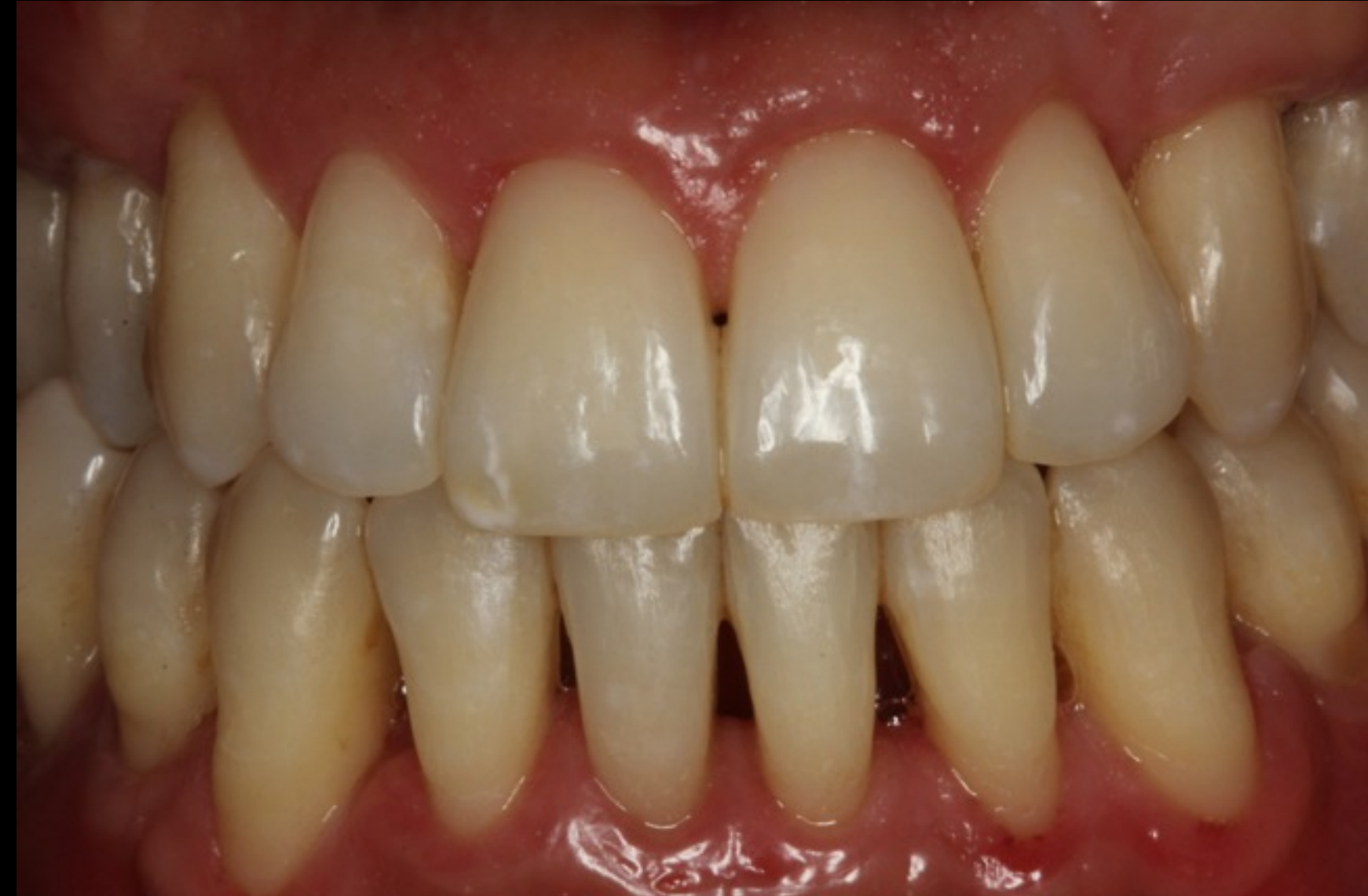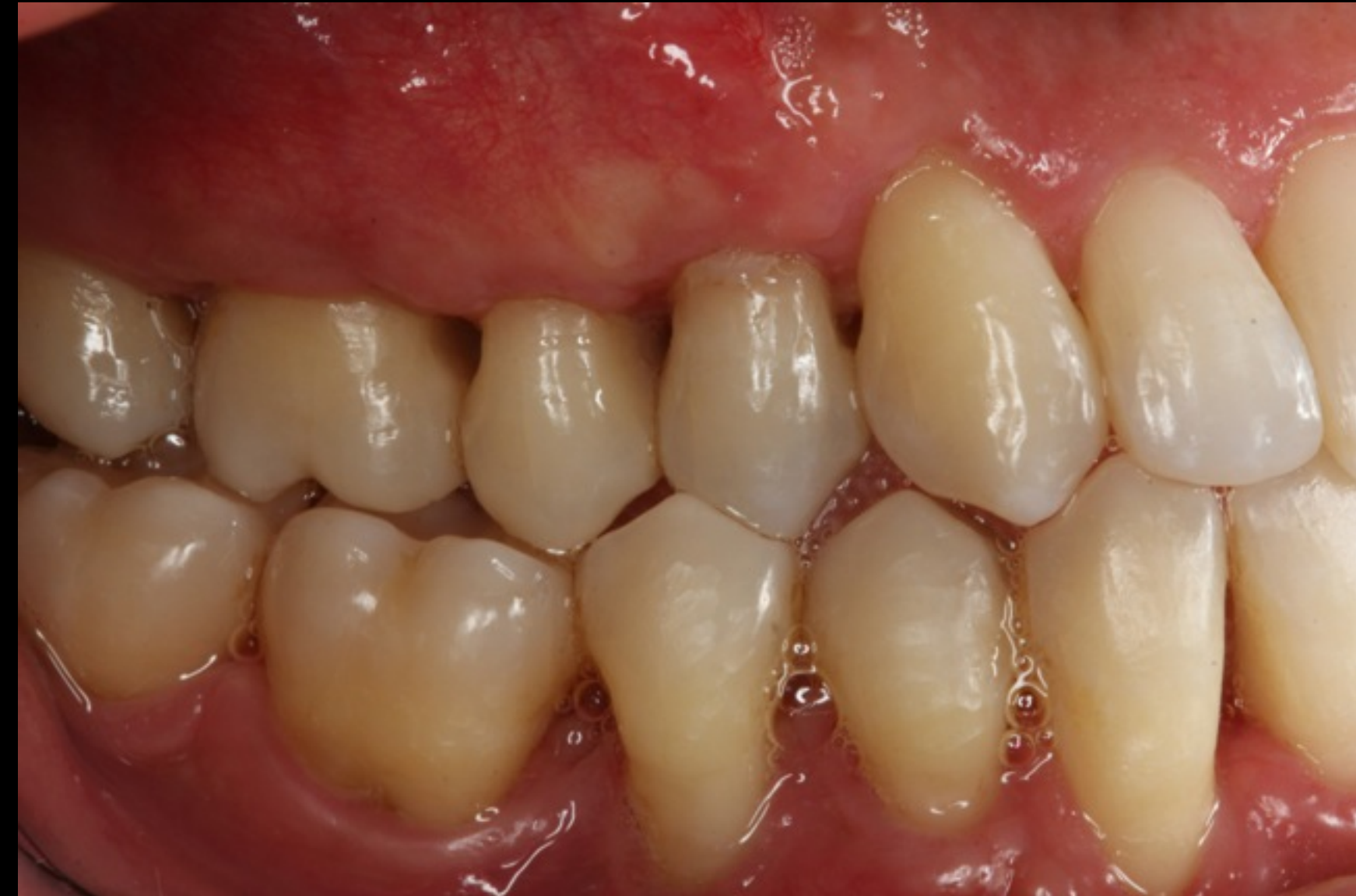12 months Post Op



1 year Post Op

Outcome Assessment

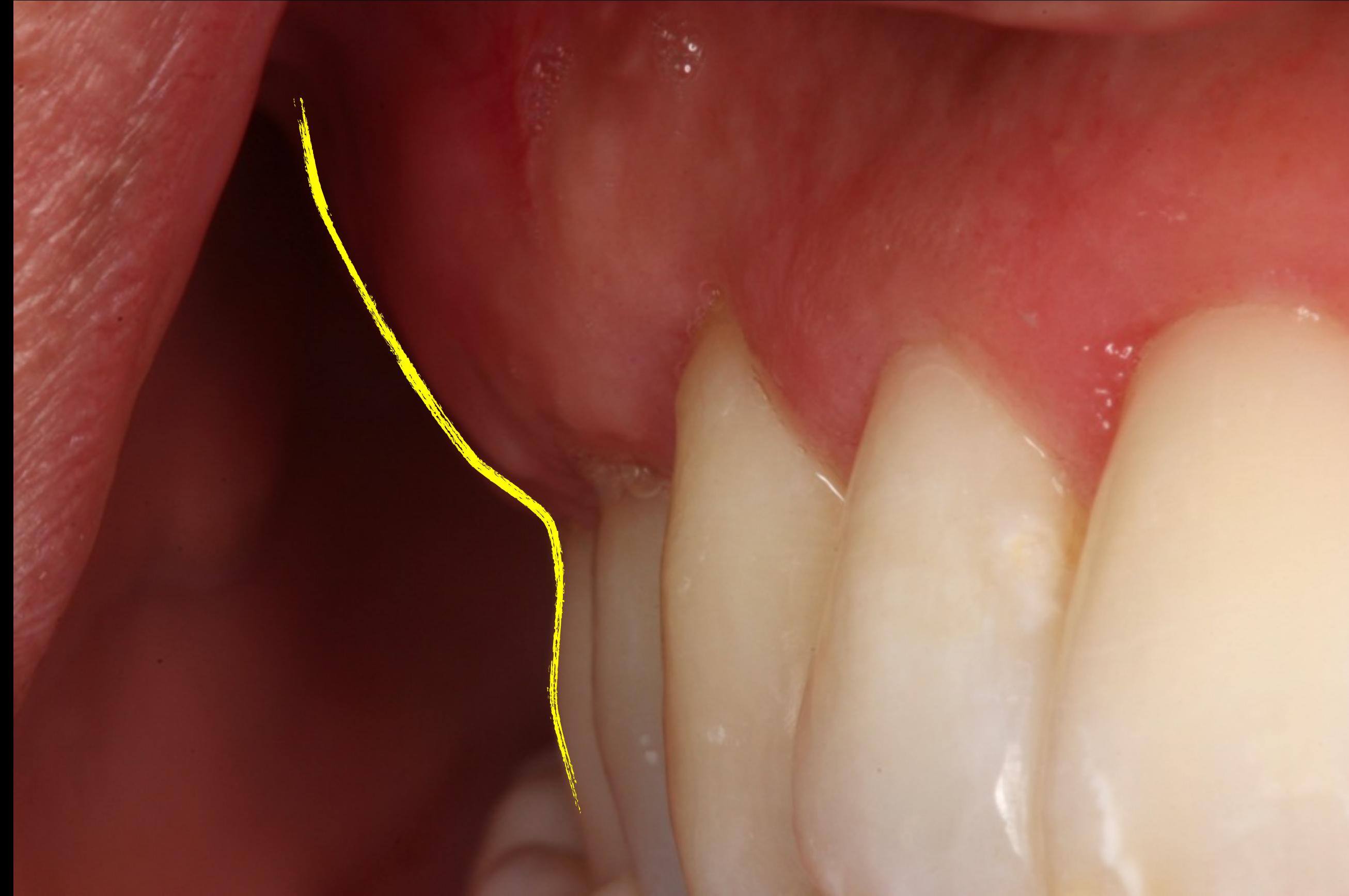
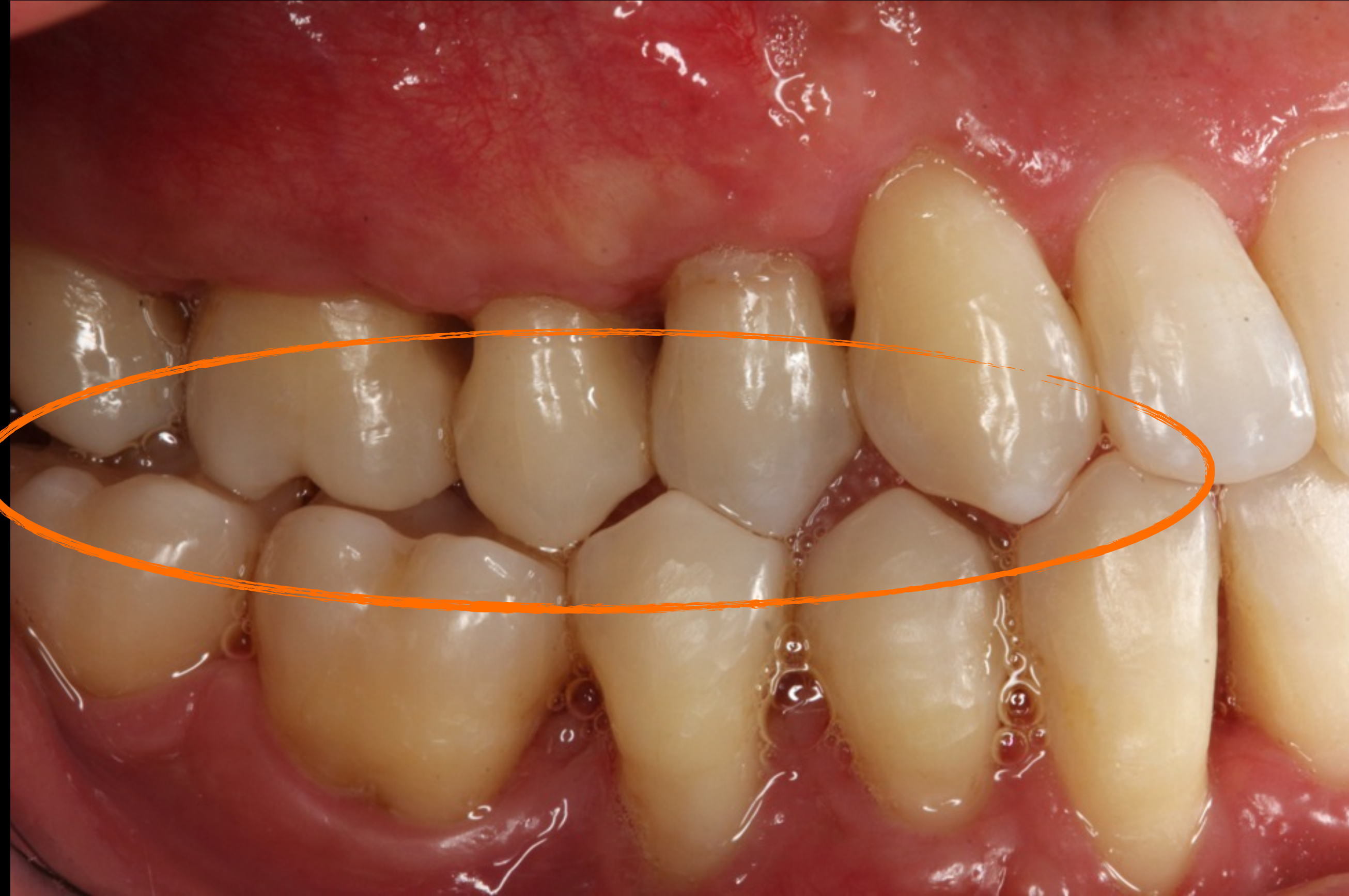
Dentoalveolar bone changes



1 year post SFOF - maxilla

Outcome Assessment

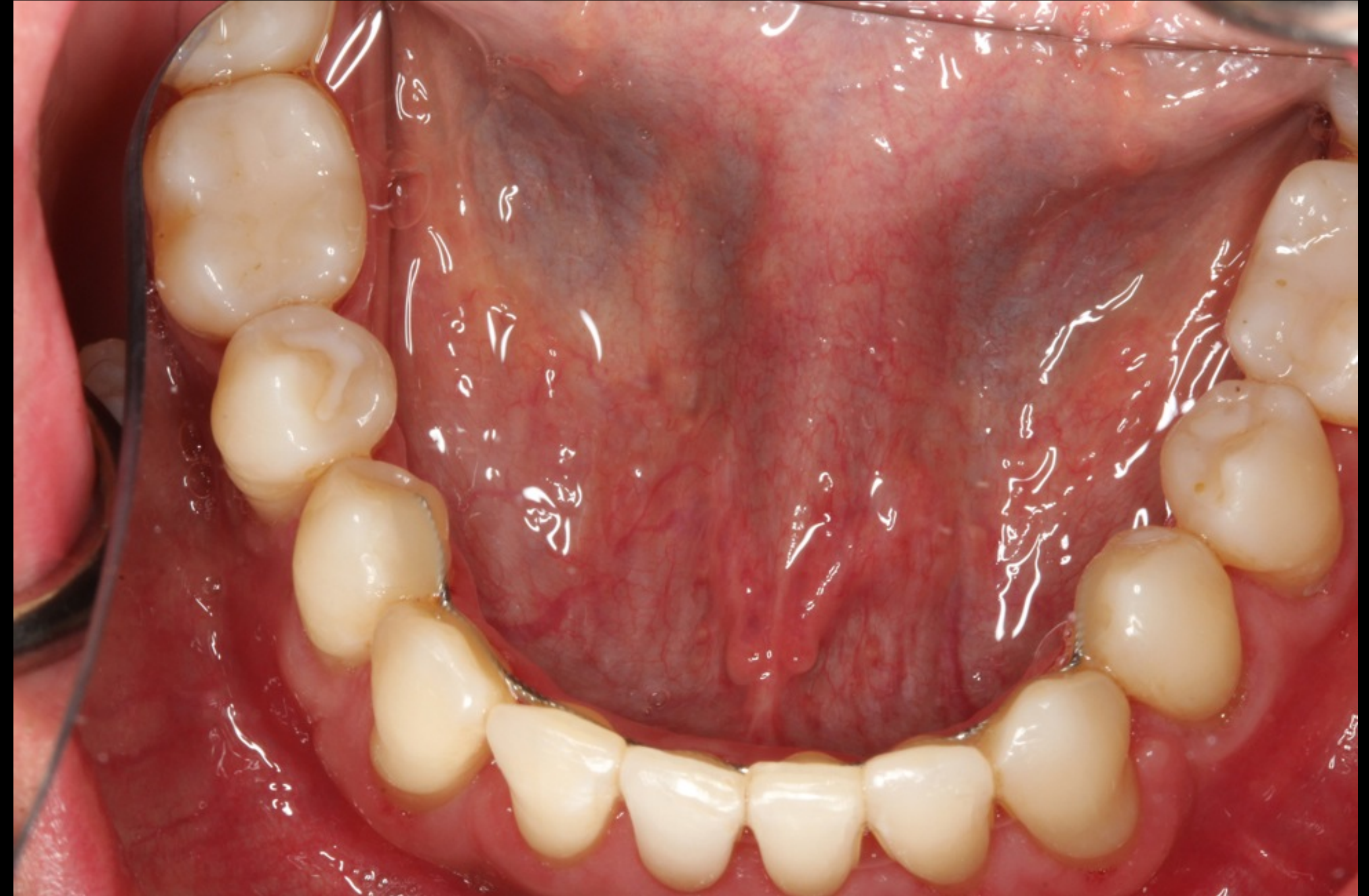
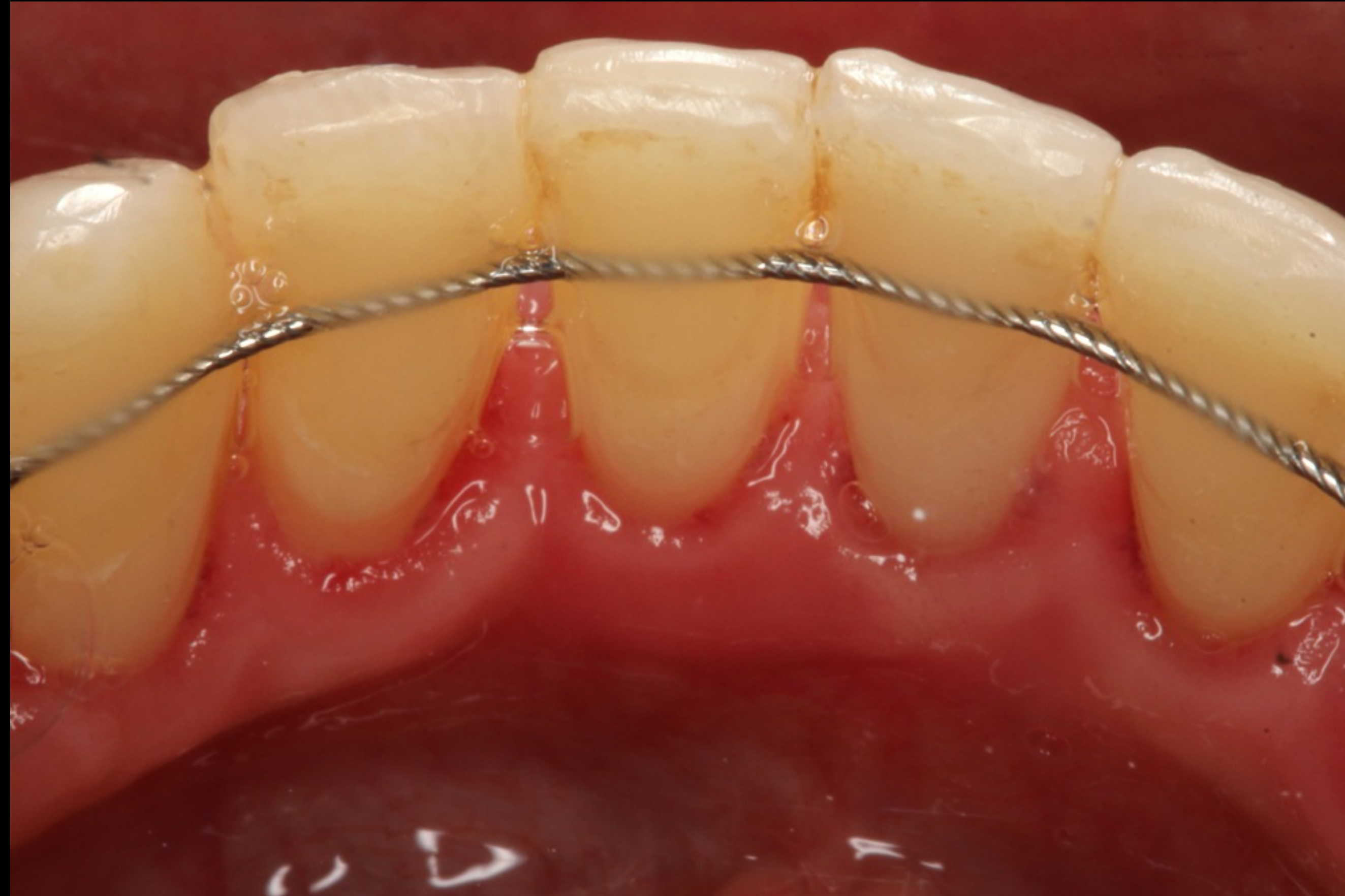Dentoalveolar bone changes



1 year post SFOF - maxilla

Outcome Assessment

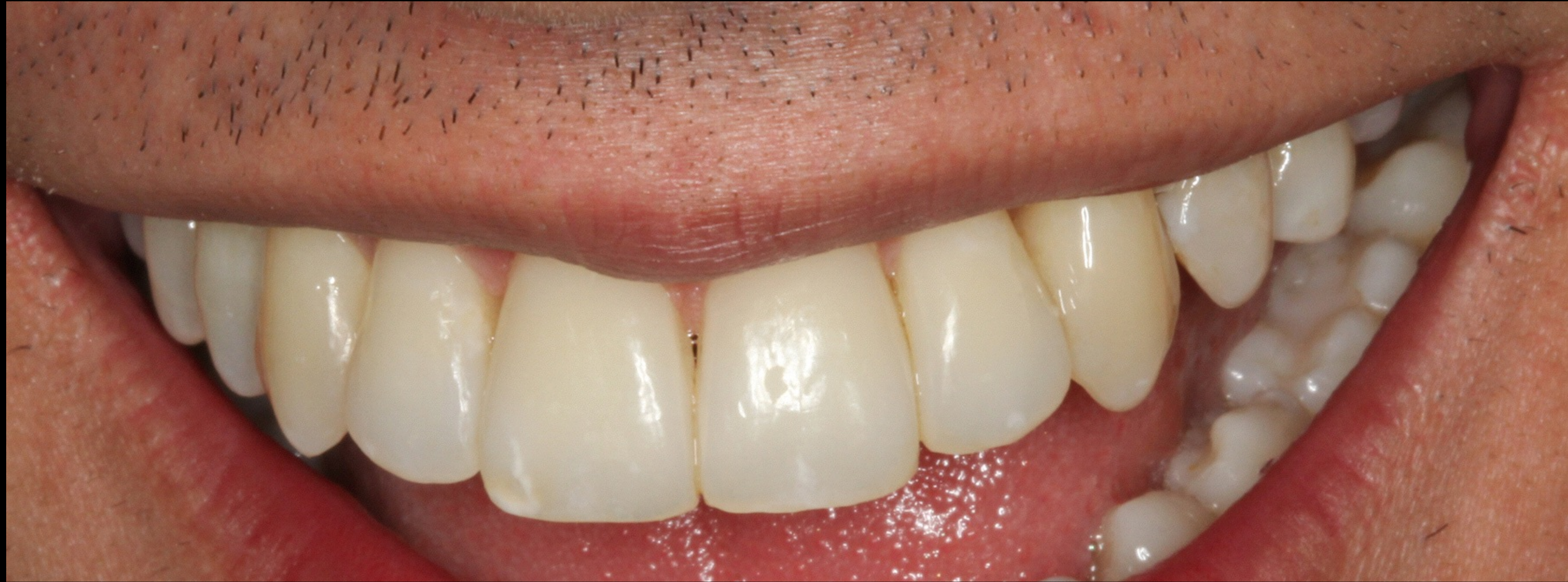Dentoalveolar bone changes



1 year post SFOF - maxilla

Outcome Assessment

Dentoalveolar bone changes



1 year post SFOF - maxilla