

rhBMP-2 and “cross talk”. A case report involving a single tooth dental implant for replacement of #4

Implant placement + rhBMP-2 for sinus augmentation
Progressive bone maturation and response to functional loading @ 15 months

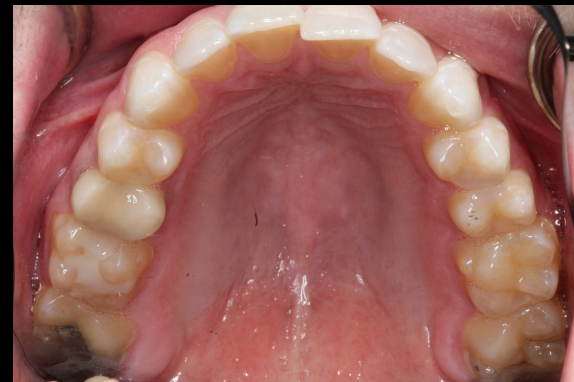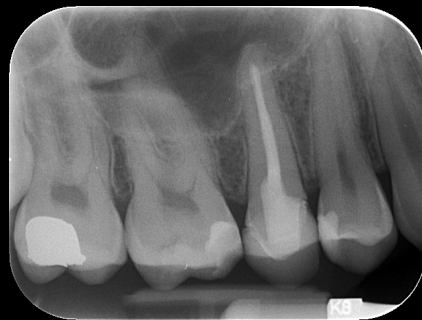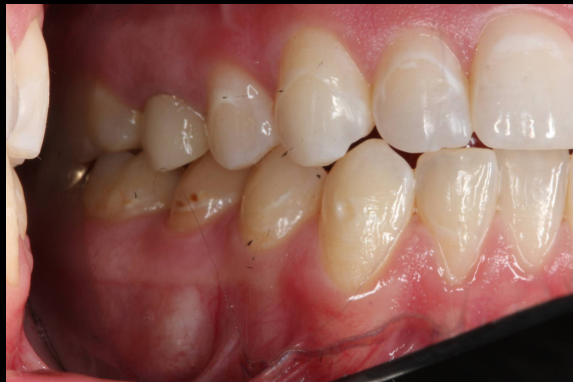George Mandelaris, DDS, MS



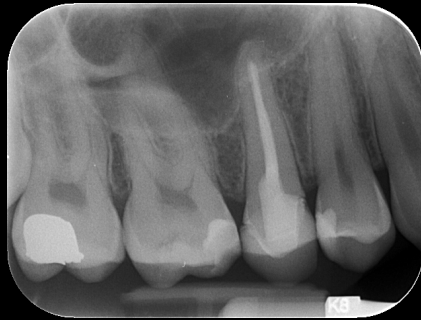PERIODONTAL | Surgical
Medicine | SPECIALISTS

Initial Exam

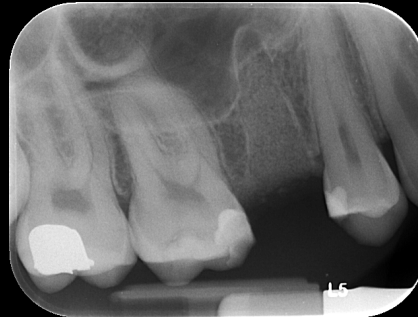
Fracture identified #4



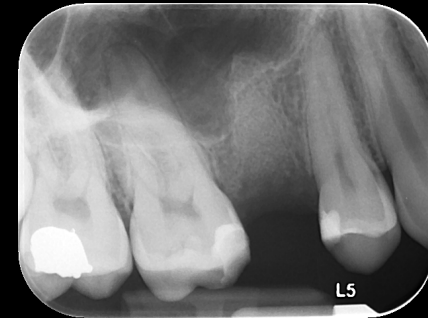Pre Op. Fracture #4 (internal)
July 1, 2011



Socket bone grafting #4 via Puros cancellous allograft
July 1, 2011



Socket bone grafting #4 via allograft
September 27, 2011



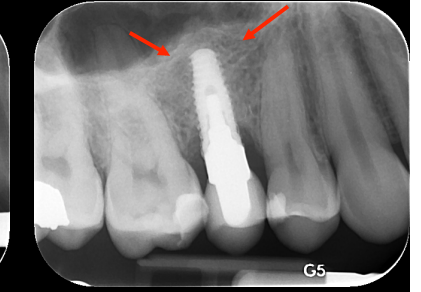
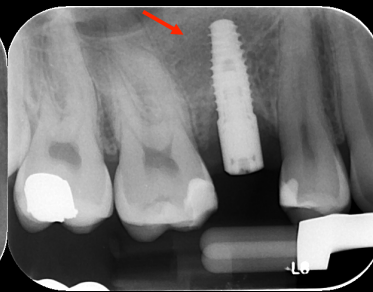
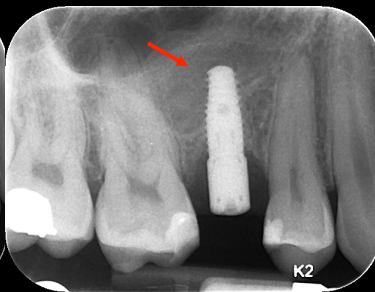
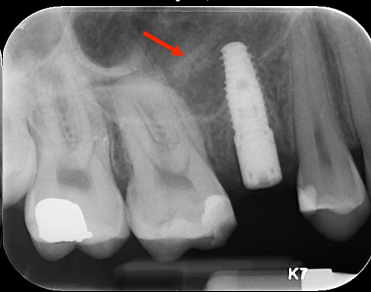
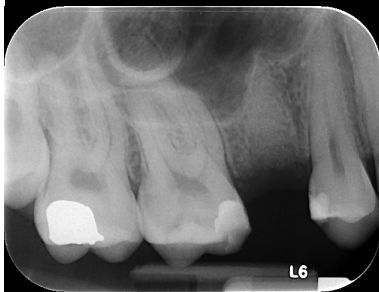
6 month socket graft healing. Directly pre op
implant + sinus augmentation
January 27, 2012

Simultaneous implant placement #4 + lateral
window sinus augmentation with rhBMP-2
+ Puros allograft. Post op PA
January 27, 2012

4 month progress PA
May 18, 2012

6 month progress PA
July 13, 2012

11 month post loading PA
June 6, 2013



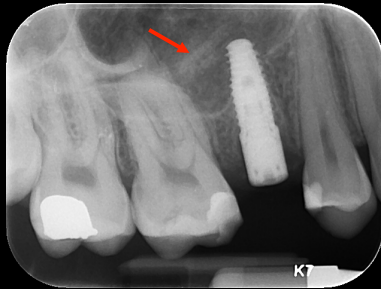
Implant placement + rhBMP-2 for sinus augmentation
Progressive bone maturation and response to functional loading over nearly 1 year

Crestal loss due to excess cement
Or poor crestal bone unionization/consolidation

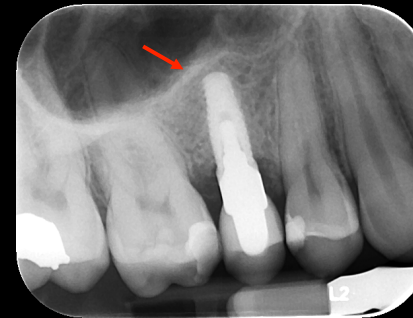

PERIODONTAL | Surgical
Medicine | SPECIALISTS

Simultaneous implant placement #4 + lateral window sinus augmentation with rhBMP-2 + Puros allograft. Post op PA
January 27, 2012



21 month post op PA
15 months post loading
10 weeks post peri-implantitis txt via regeneration with FDBA, BioOss + PDGF
October 4, 2013

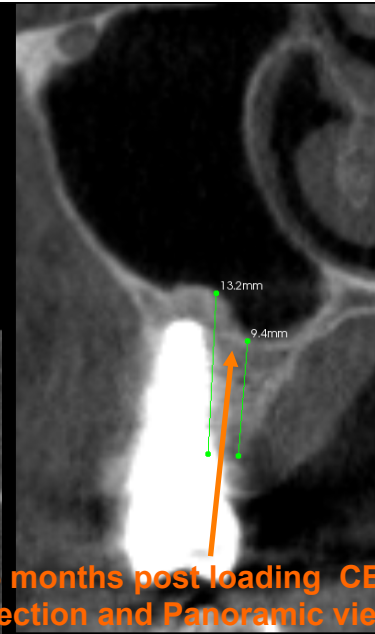
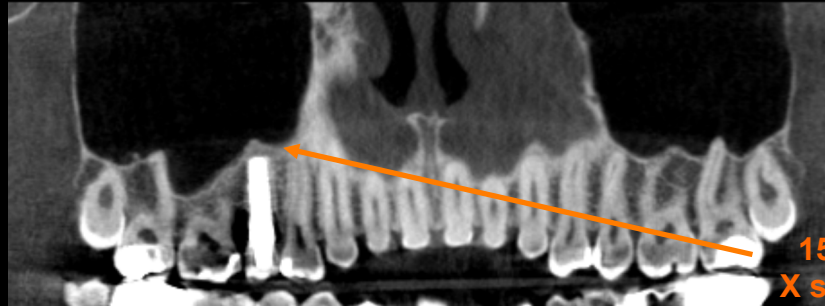
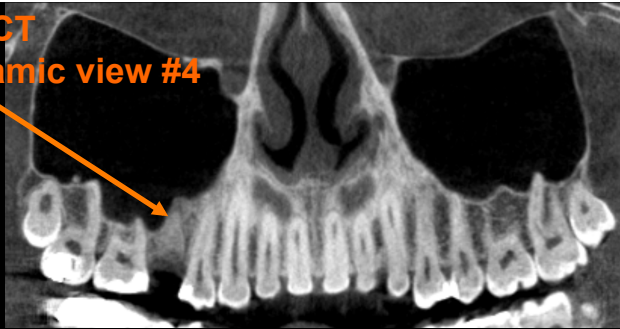
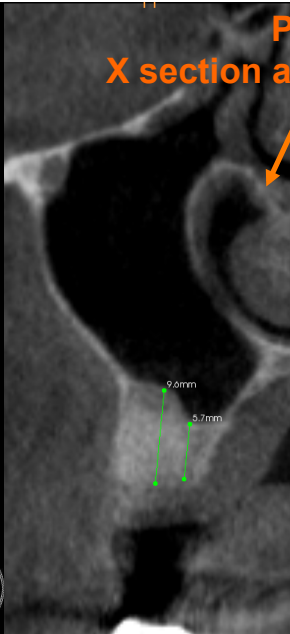

**Implant placement + rhBMP-2 for sinus augmentation.
Progressive bone maturation and response to functional
loading @ 15 months**



PERIODONTAL | Surgical
Medicine | SPECIALISTS

Pre Op CBCT
X section and Panoramic view #4



15 months post loading CBCT
X section and Panoramic view #4



Oral Surgical Specialists