

Tissue Engineering for Bone Reconstruction in Implant Site Development

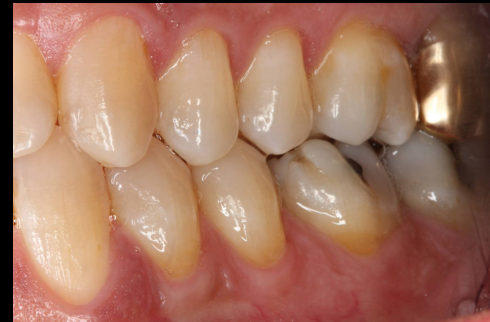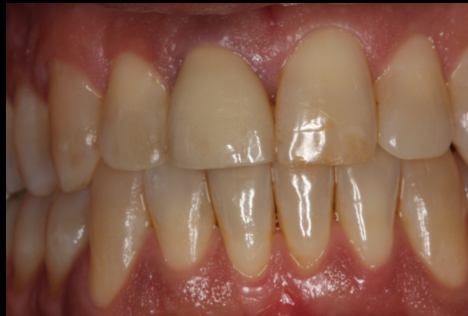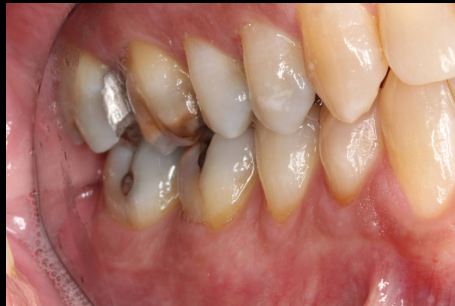+

CT Guided Implant Placement

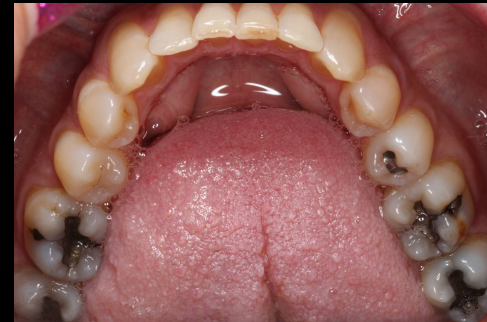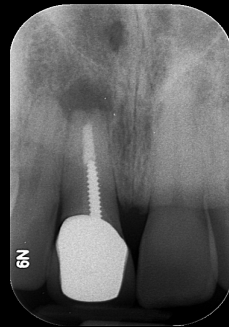

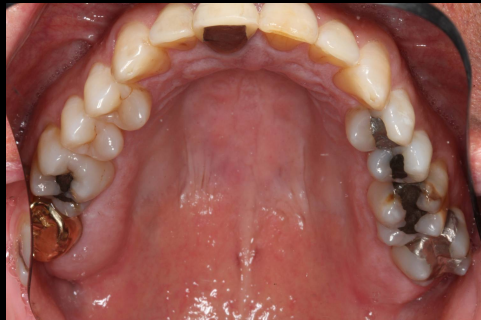
PERIODONTAL | Surgical
Medicine | SPECIALISTS

Initial Examination



Initial Examination



Diagnoses

- Localized moderate-advanced chronic periodontitis
- Periapical pathology #8- recurrent
- Thin crestal with thin radicular dentoalveolar bone phenotype

Prognoses

- #8 = poor/hopeless
- All else- fair/good pending specialty periodontal treatment

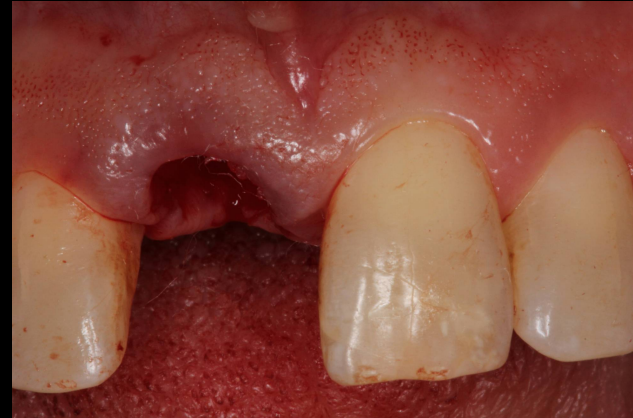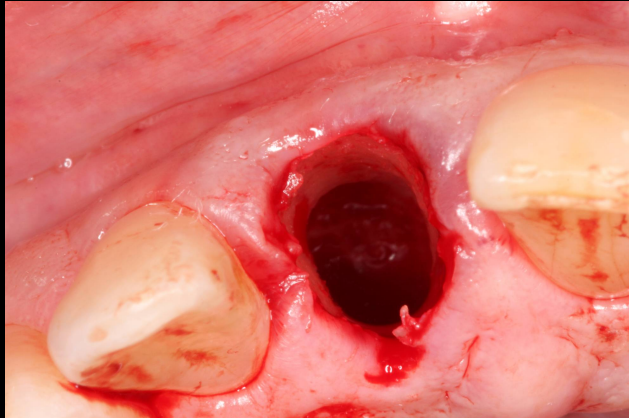


Treatment Plan specific to #8

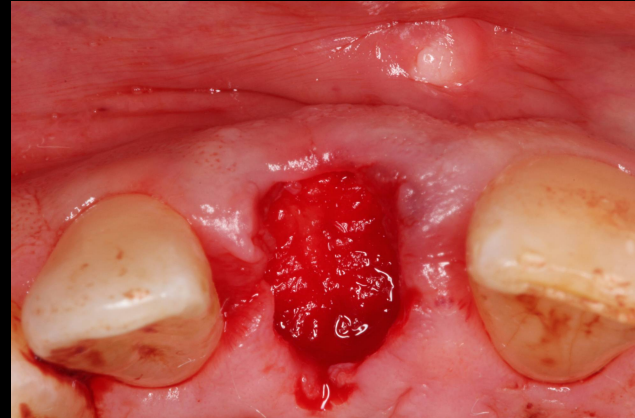
- Phase I Surgery: Atraumatic surgical extraction of #8 + bone regeneration via rhBMP-2
 - Cone Beam CT scan
 - Phase II Surgery: CT guided implant placement + immediate non-occlusal function provisional. Soft tissue augmentation via autogenous connective tissue grafting.
 - Final prosthetic phase completion



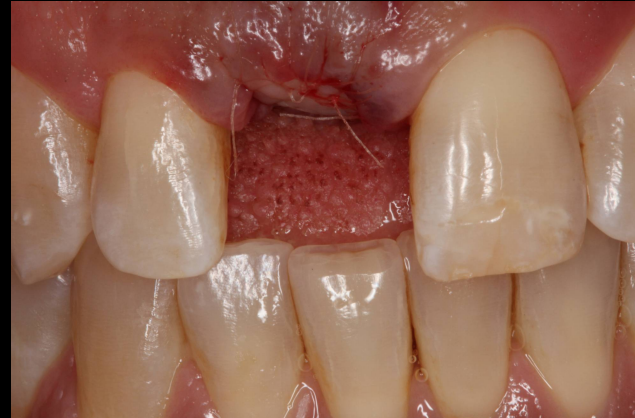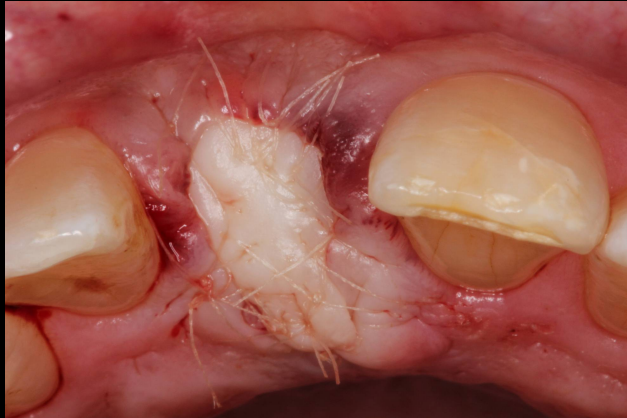Phase I- Surgery



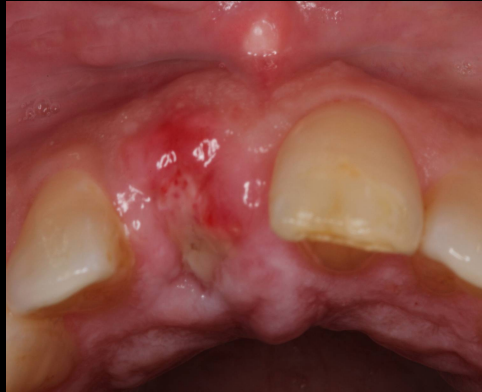Phase I- Surgery



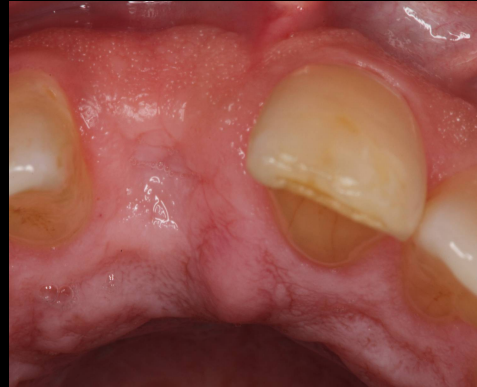Phase I- Surgery



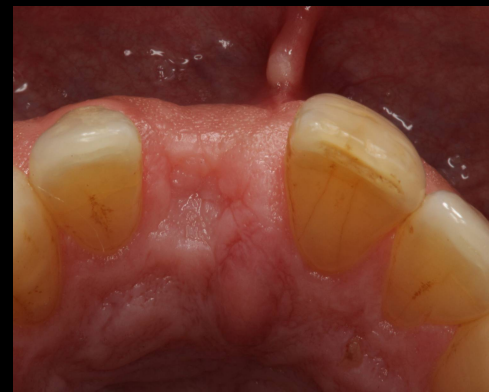2 weeks post op



12 weeks post op

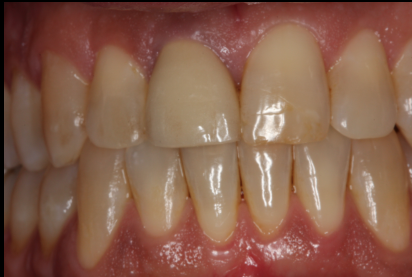

24 weeks post op

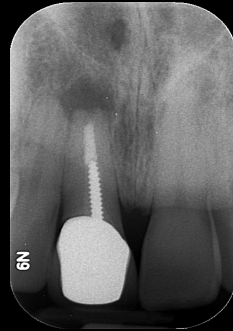


Outcome Assessment

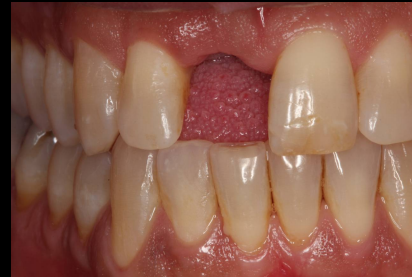Pre Op



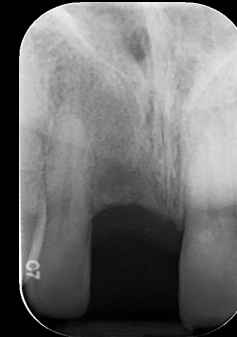
Pre Op PA



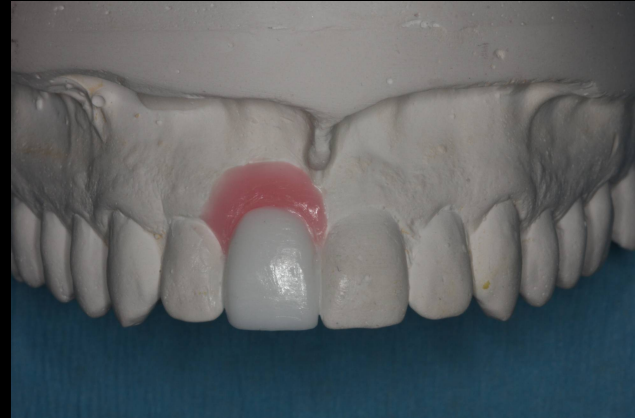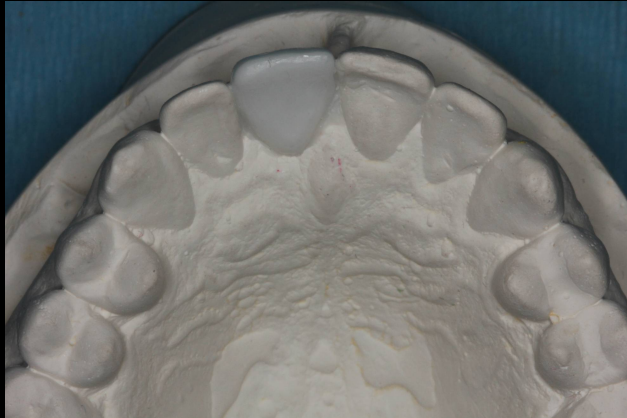Outcome



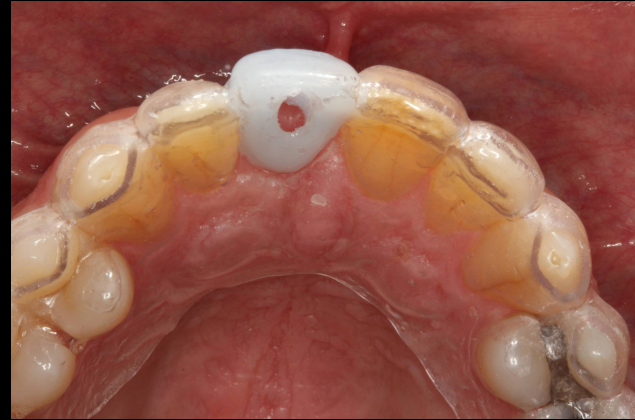
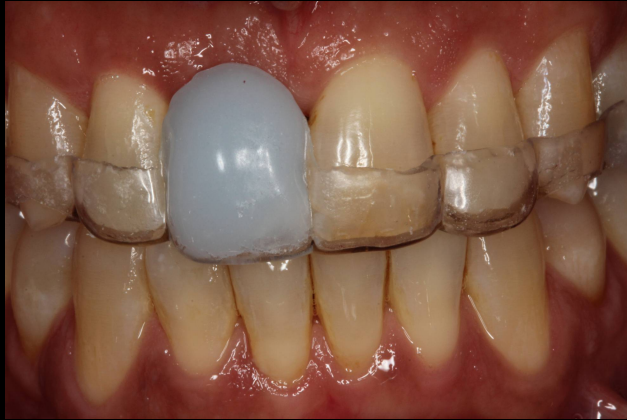Outcome PA



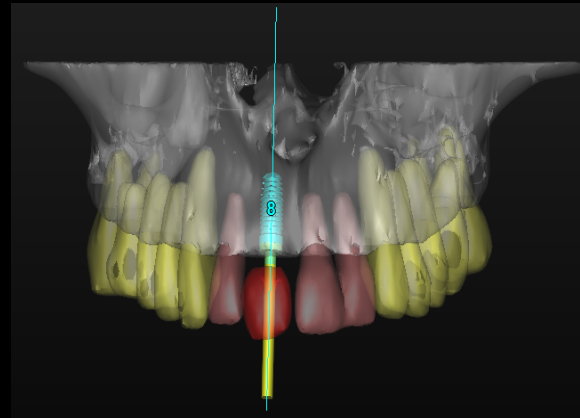
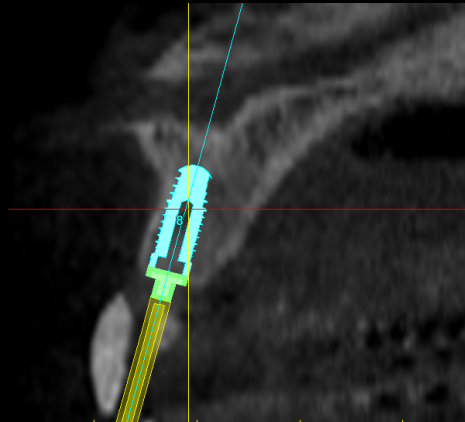
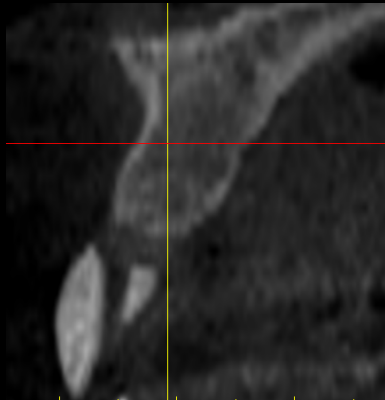
Implant Diagnostics



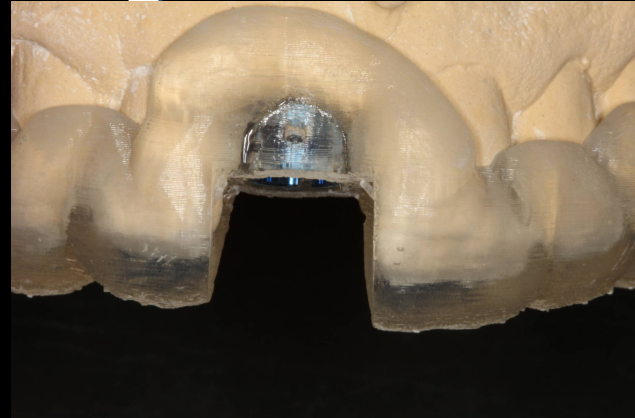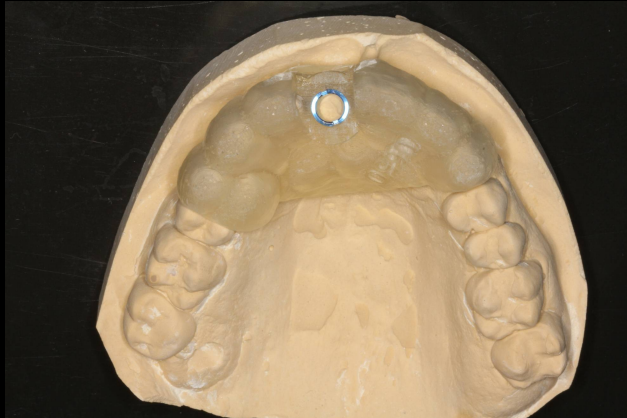
CBCT Scanning Diagnostics



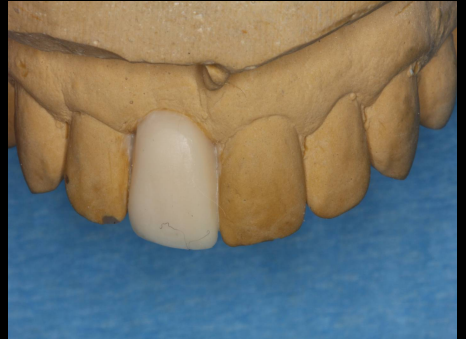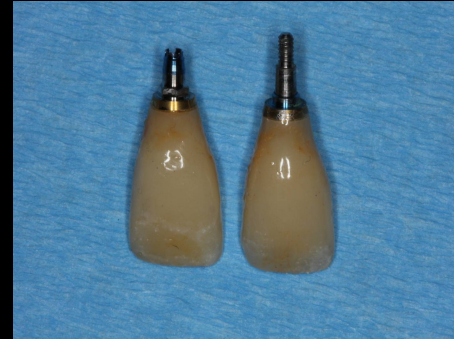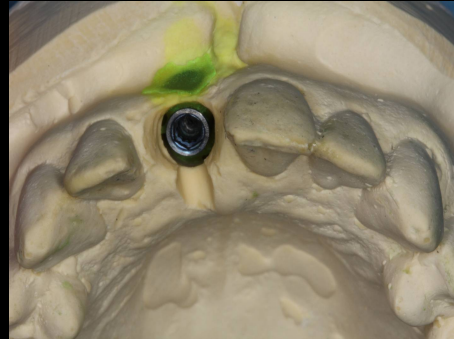
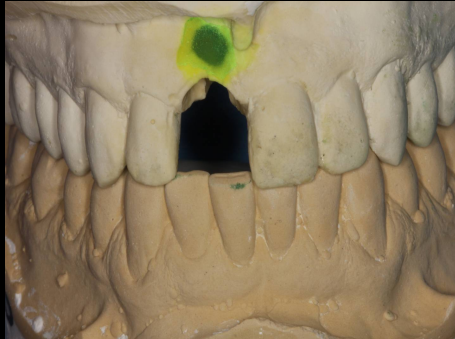
CBCT DIAGNOSTICS



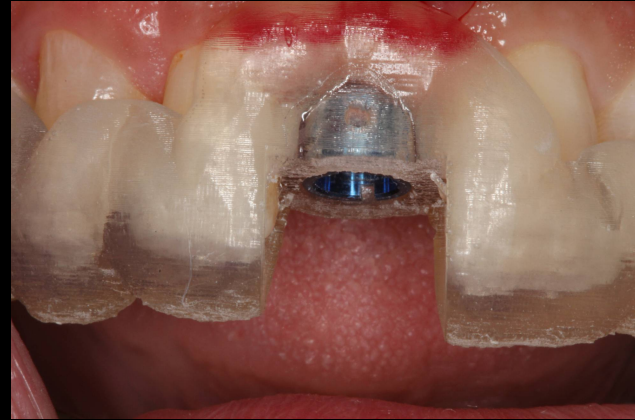
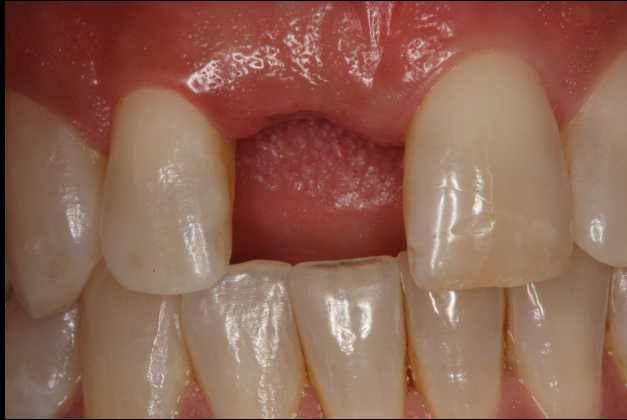Phase II-Surgery 3i and Materalise Surgi-Guide



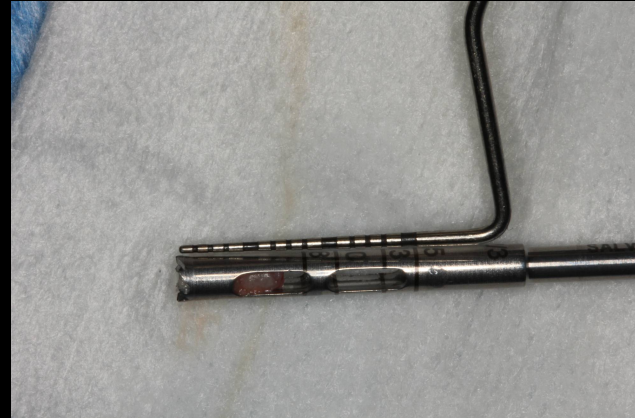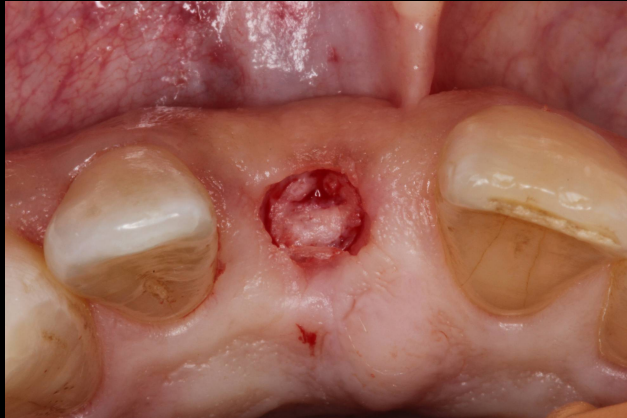
Immediate Provisional



Phase II- Surgery

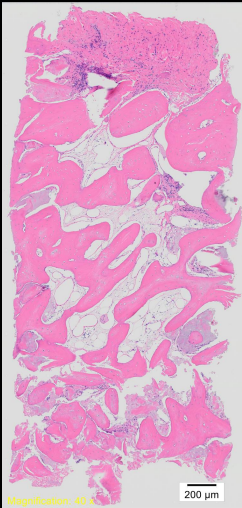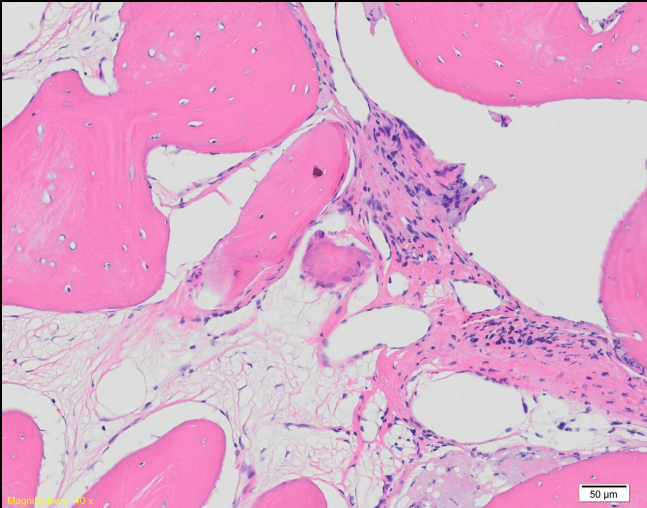


Phase II- Surgery

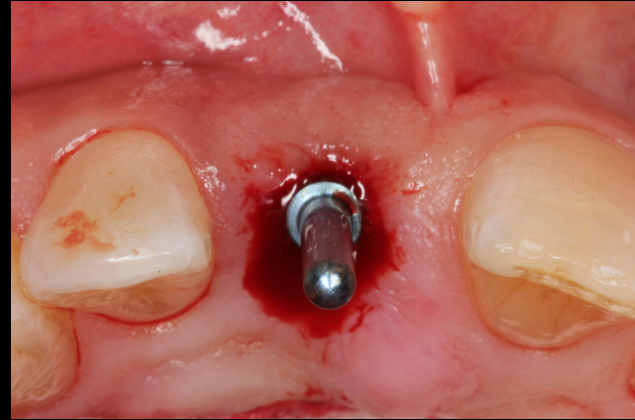
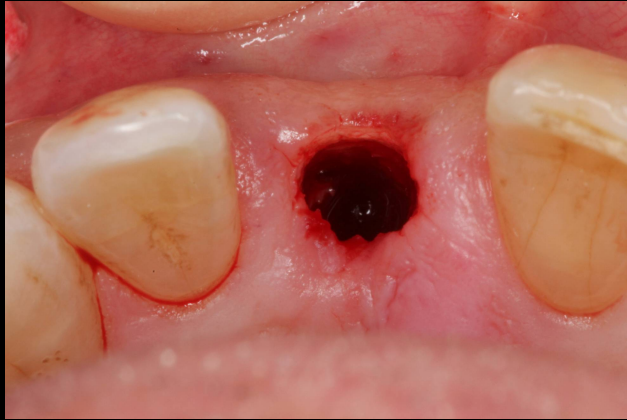


Histology

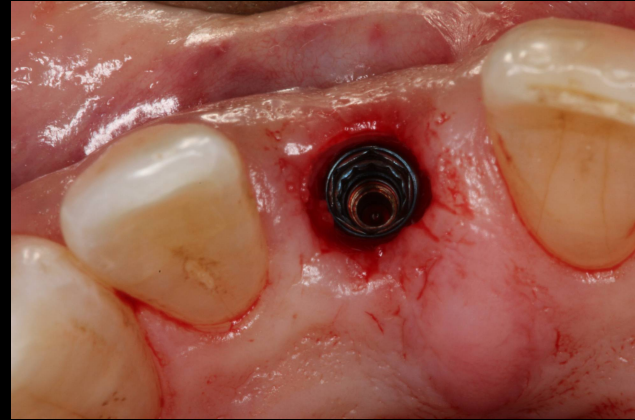
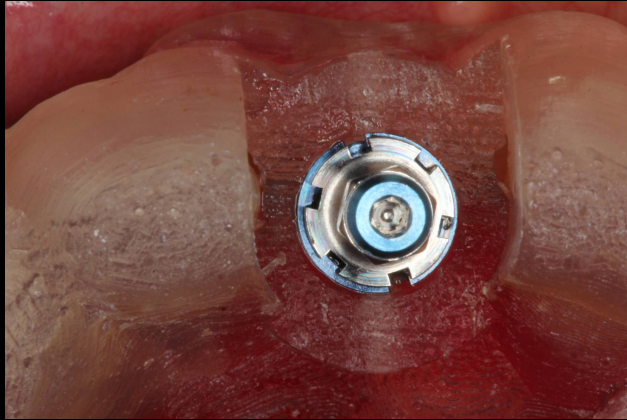
Histomorphometry:
New bone density: **47.8%**
Marrow/Cells: **52.2%**



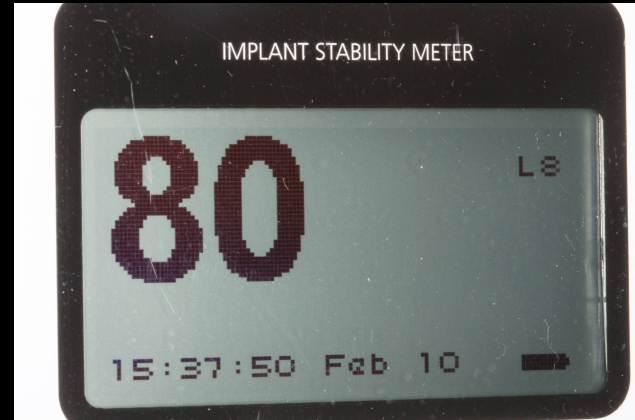
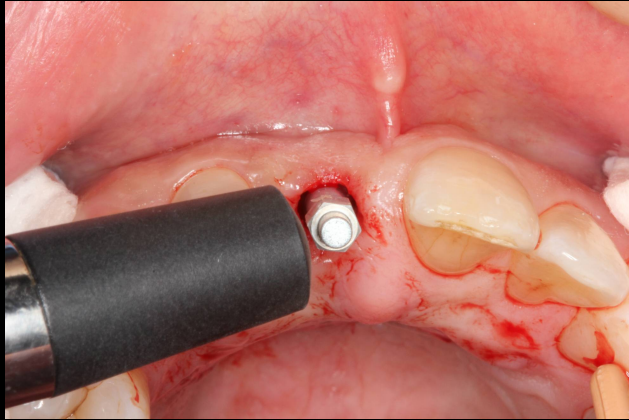
Phase II- Surgery



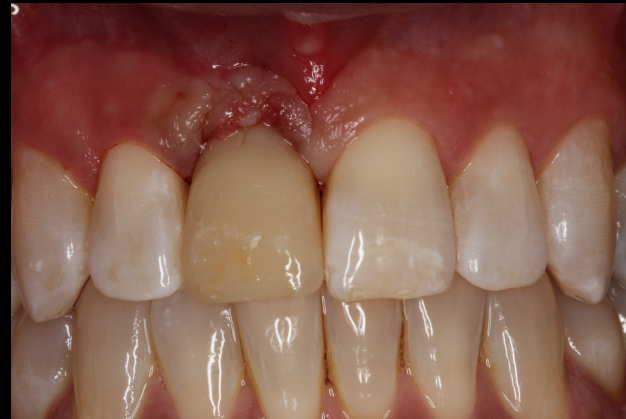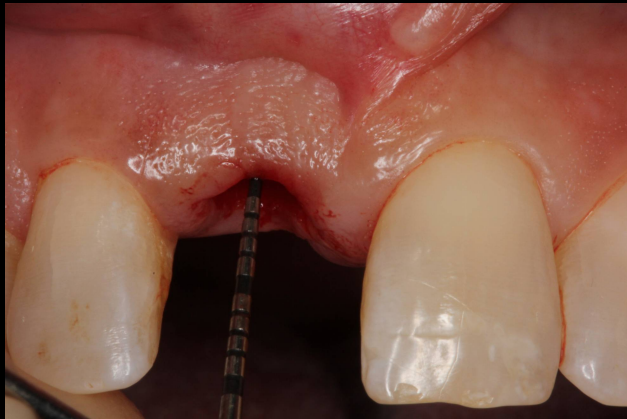Phase II- Surgery



Phase II- Surgery

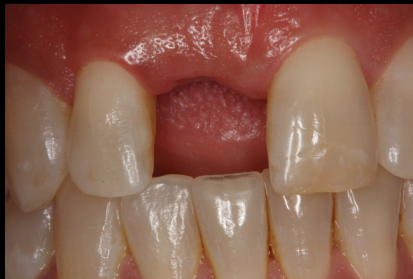

Implant placement + Immediate Provisional + CT graft

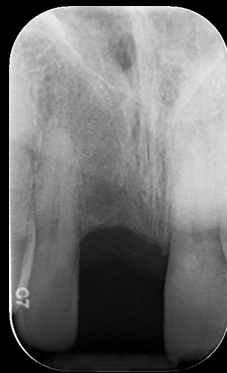

Outcome Assessment

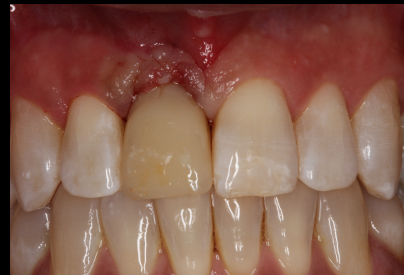Pre Op



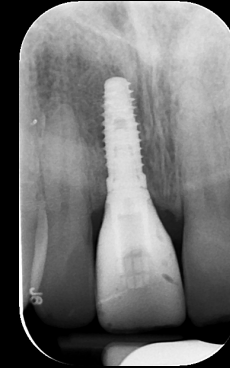
Pre Op PA



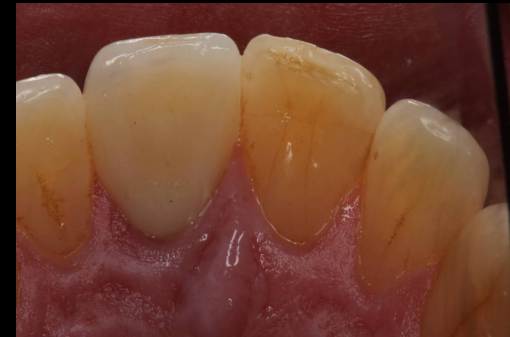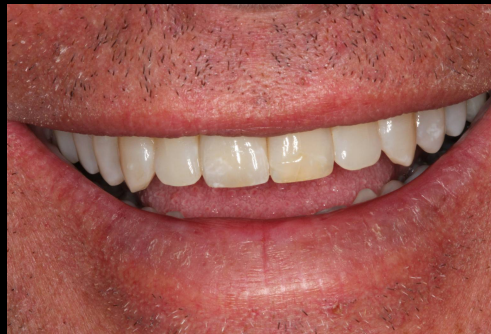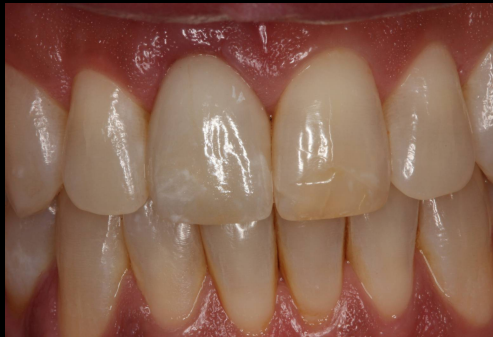Immediate Non
Occlusal Function
Provisional



Post Op PA



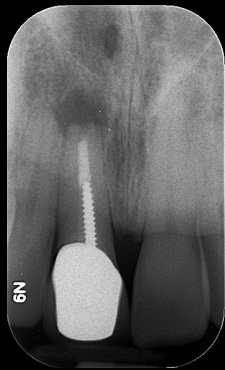
Final Prosthetics



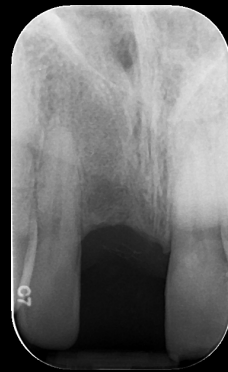Restorative Dentist: Dr. Michael Morgan (Hinsdale, IL)

PERIODONTAL | Surgical
Medicine | SPECIALISTS

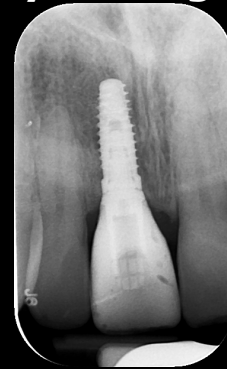
Initial Exam



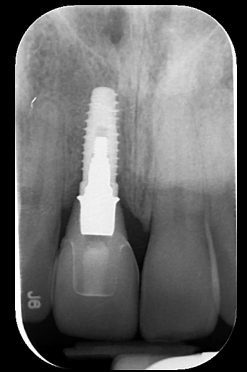**6 months post Op
rhBMP-2**



**Immediate Non
Occlusal Load
Provisional PA
(day of surgery)**



Final Outcome



PERIODONTAL | Surgical
Medicine | SPECIALISTS