

SFOT

***Transformational changes in treatment...***

**Identifier: 26 years old caucasian female**

**Chief complaint: "I am here because my dentist is concerned about gum recession"**

**Medical history: Allergies, history of Eczema**

**Current medications: Singulair, Zyrtec, Nasonex, eye drops (allergy related), Mometasone furoate**

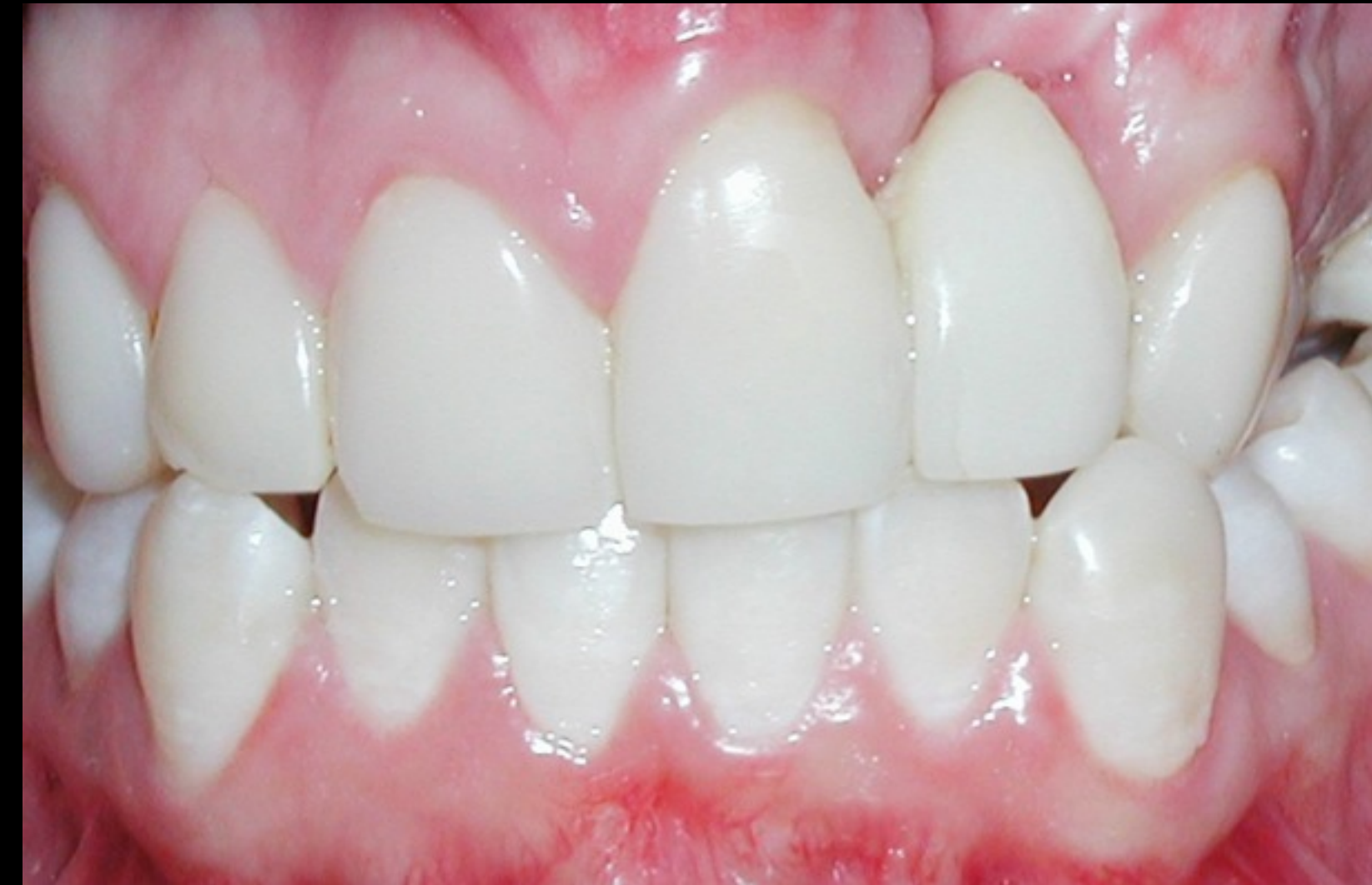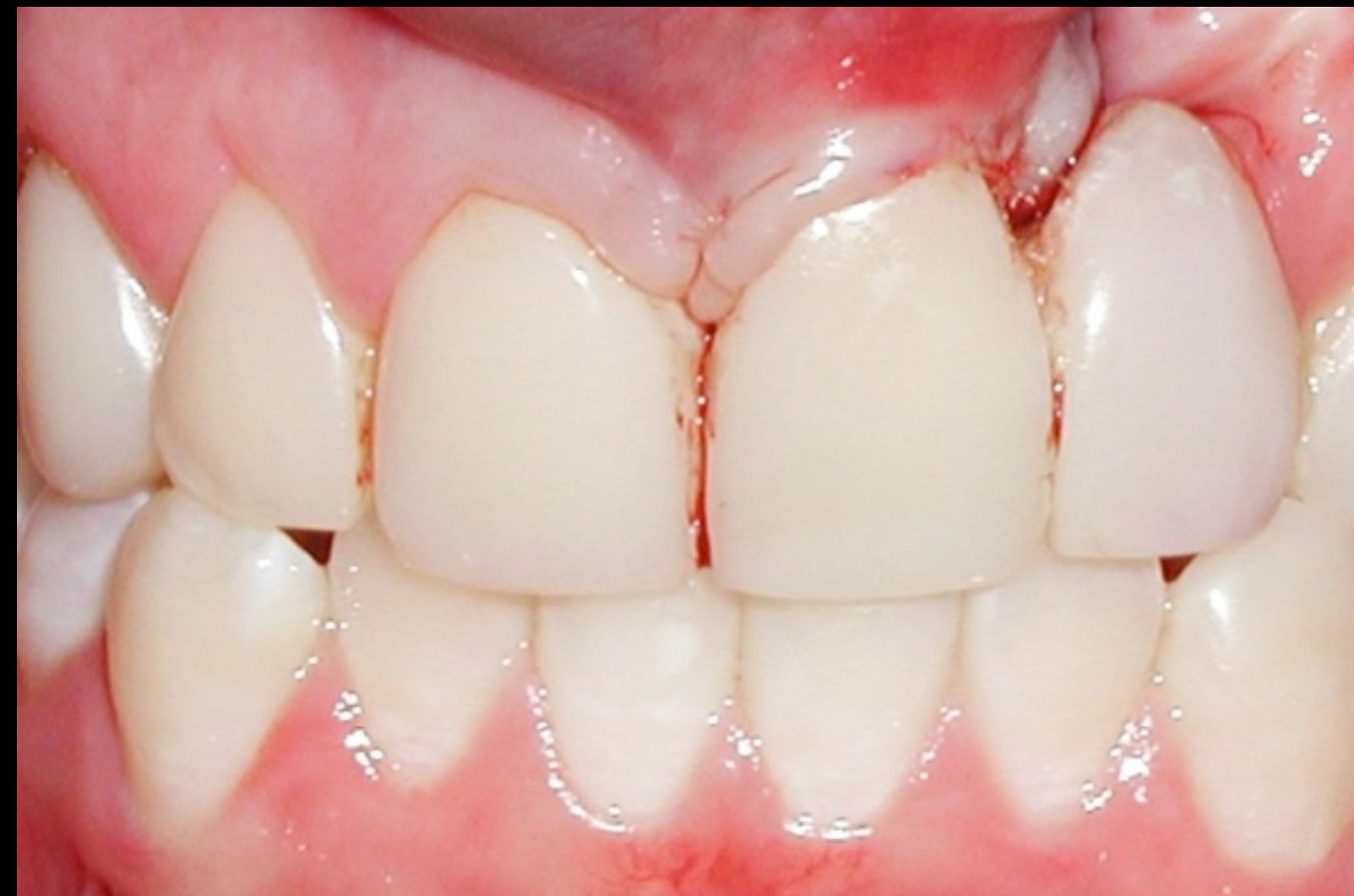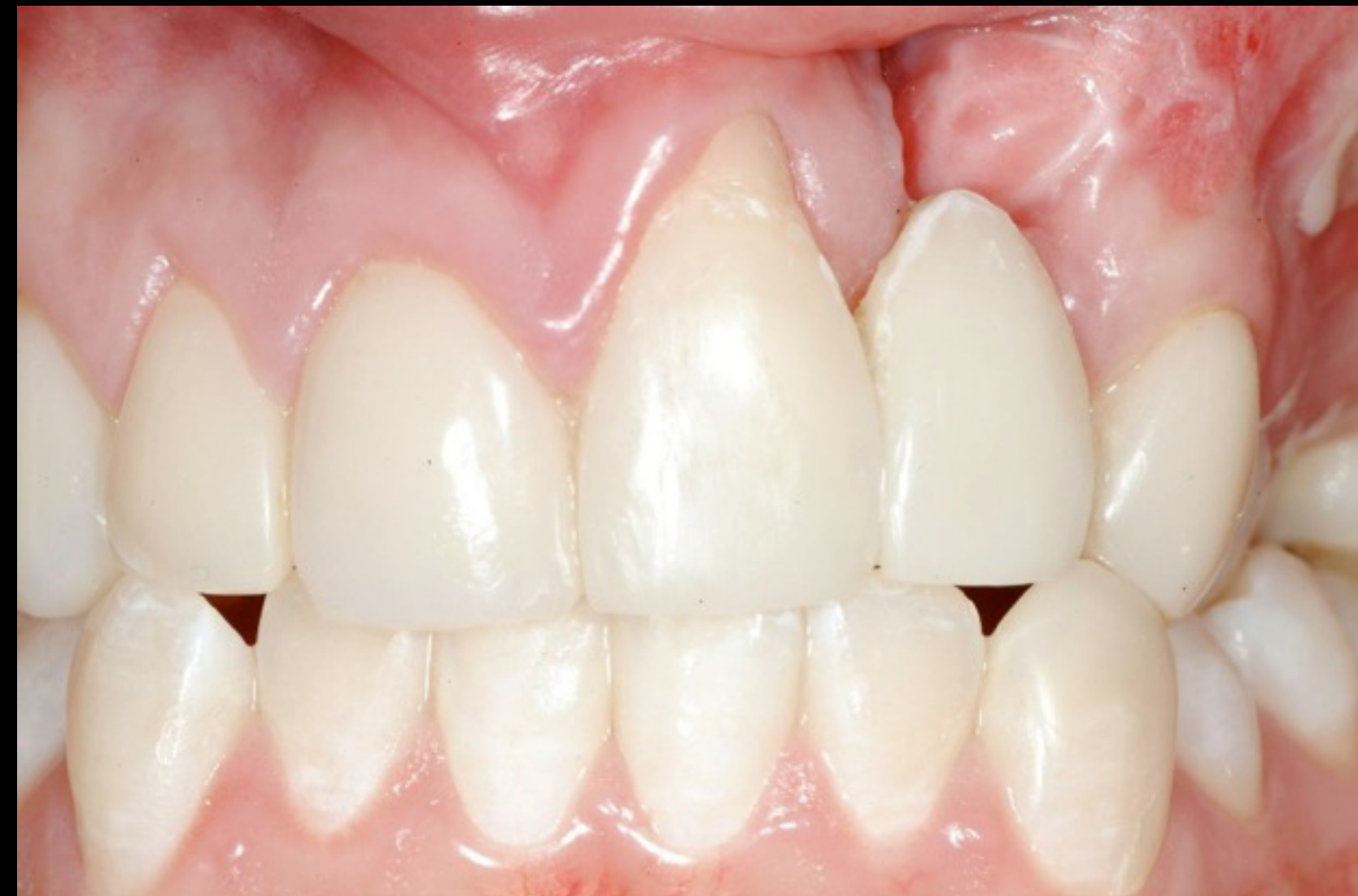**Physical status classification: ASA I**

**Congenital cleft lip – cleft palate**

**History of previous lip, alveolus and palate repair including pharyngeal flap, rib graft.alar and lip revisions.**

# *Initial Exam*

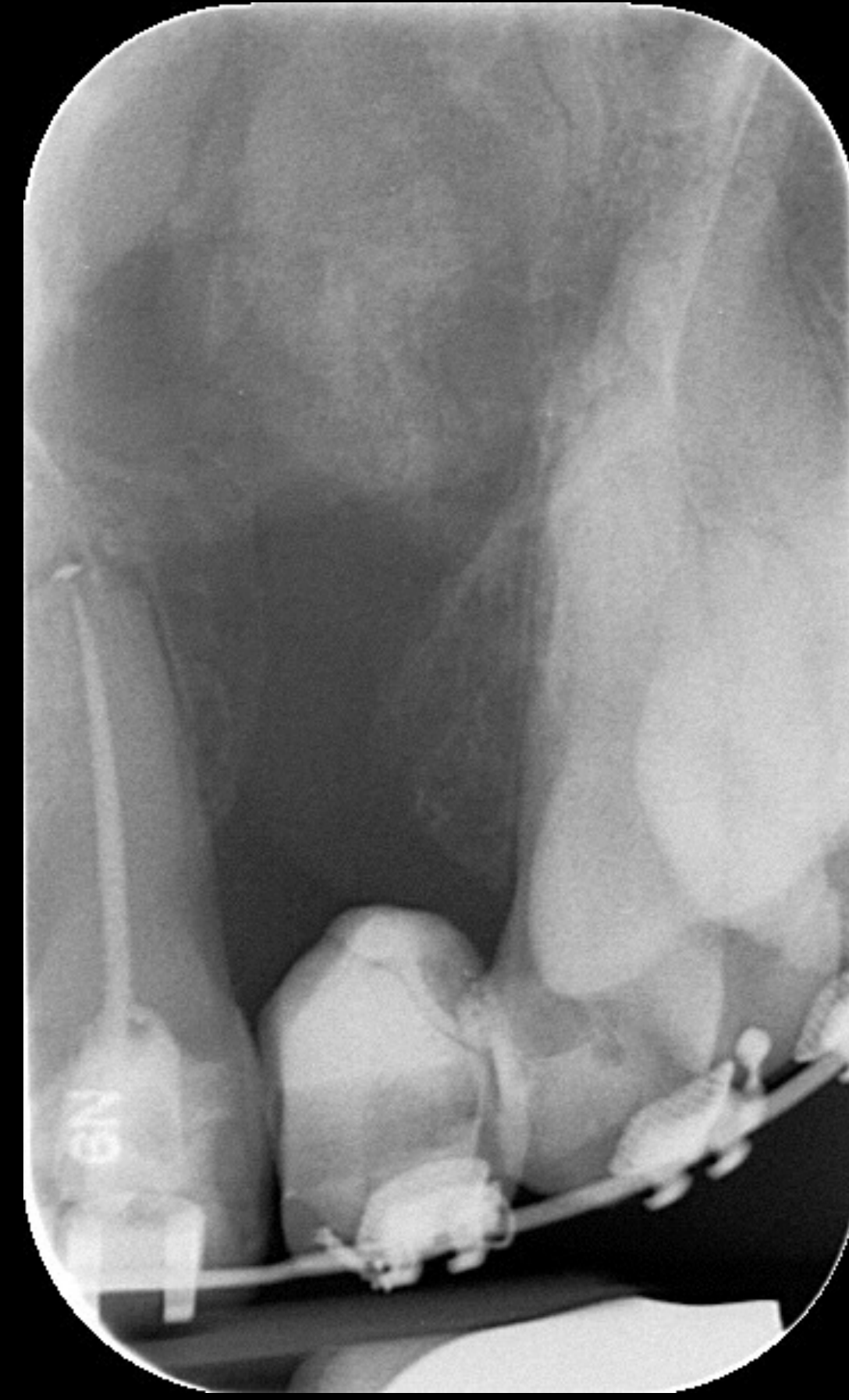
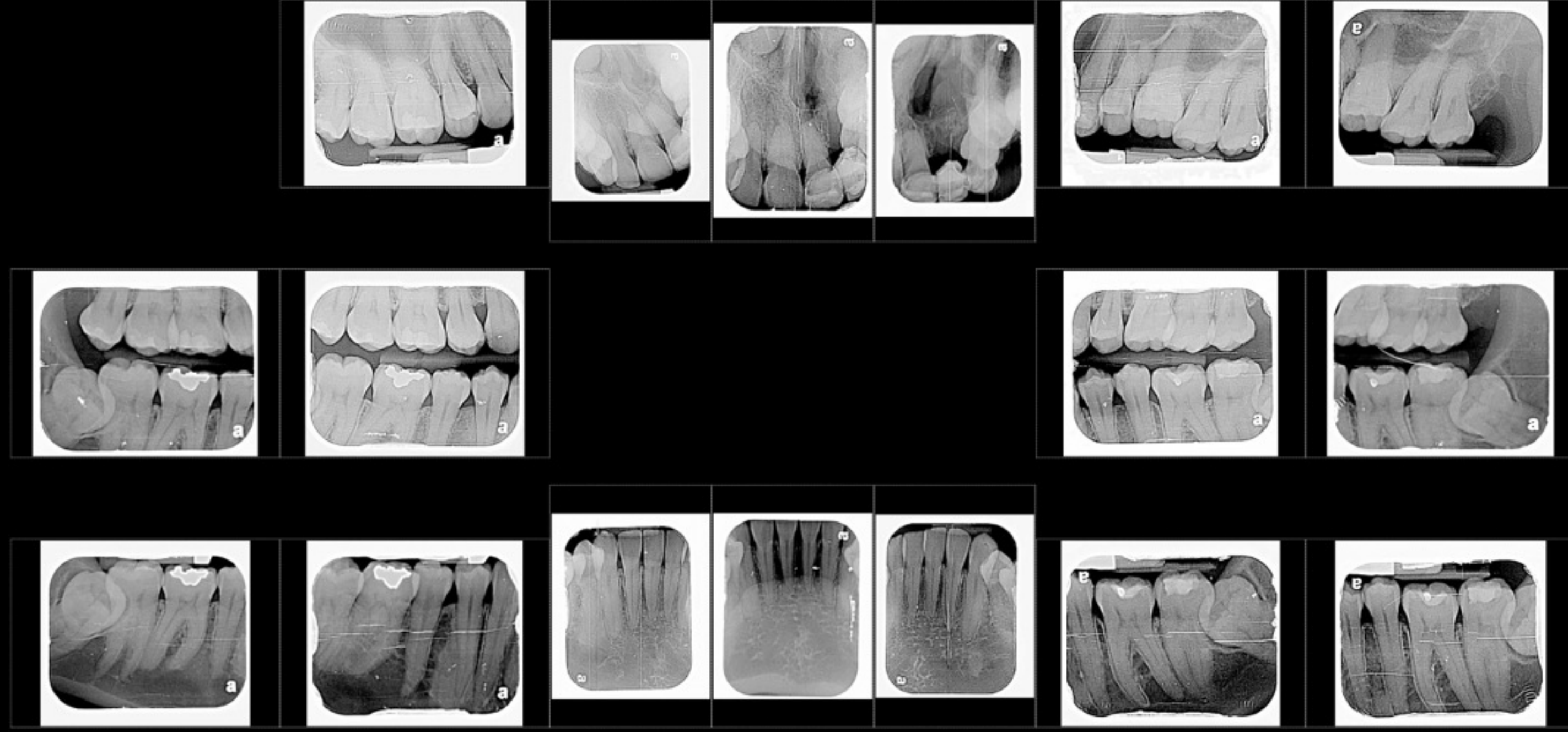*2004 Perspective*



*Root coverage*



Initial Exam - 2004

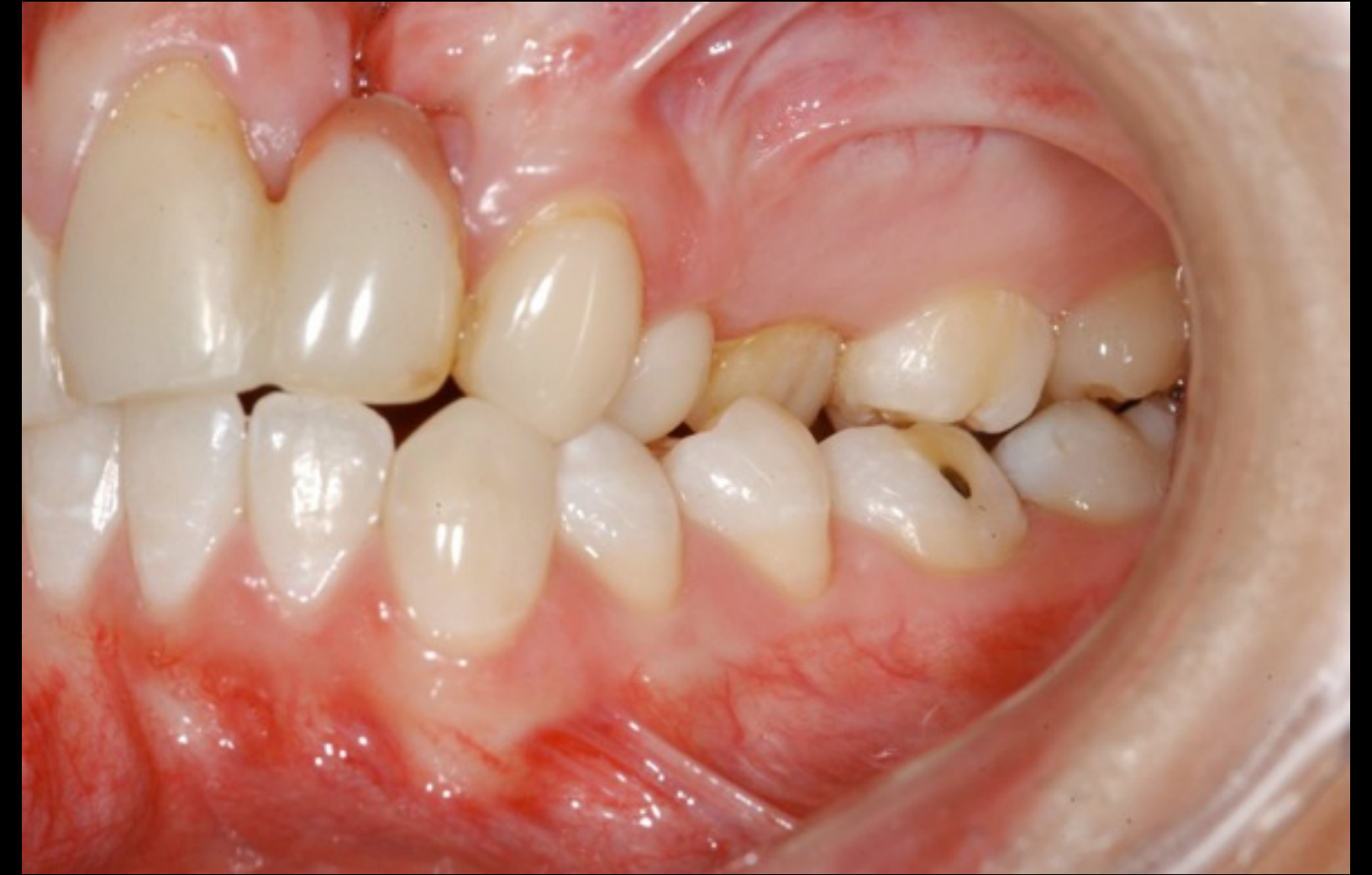
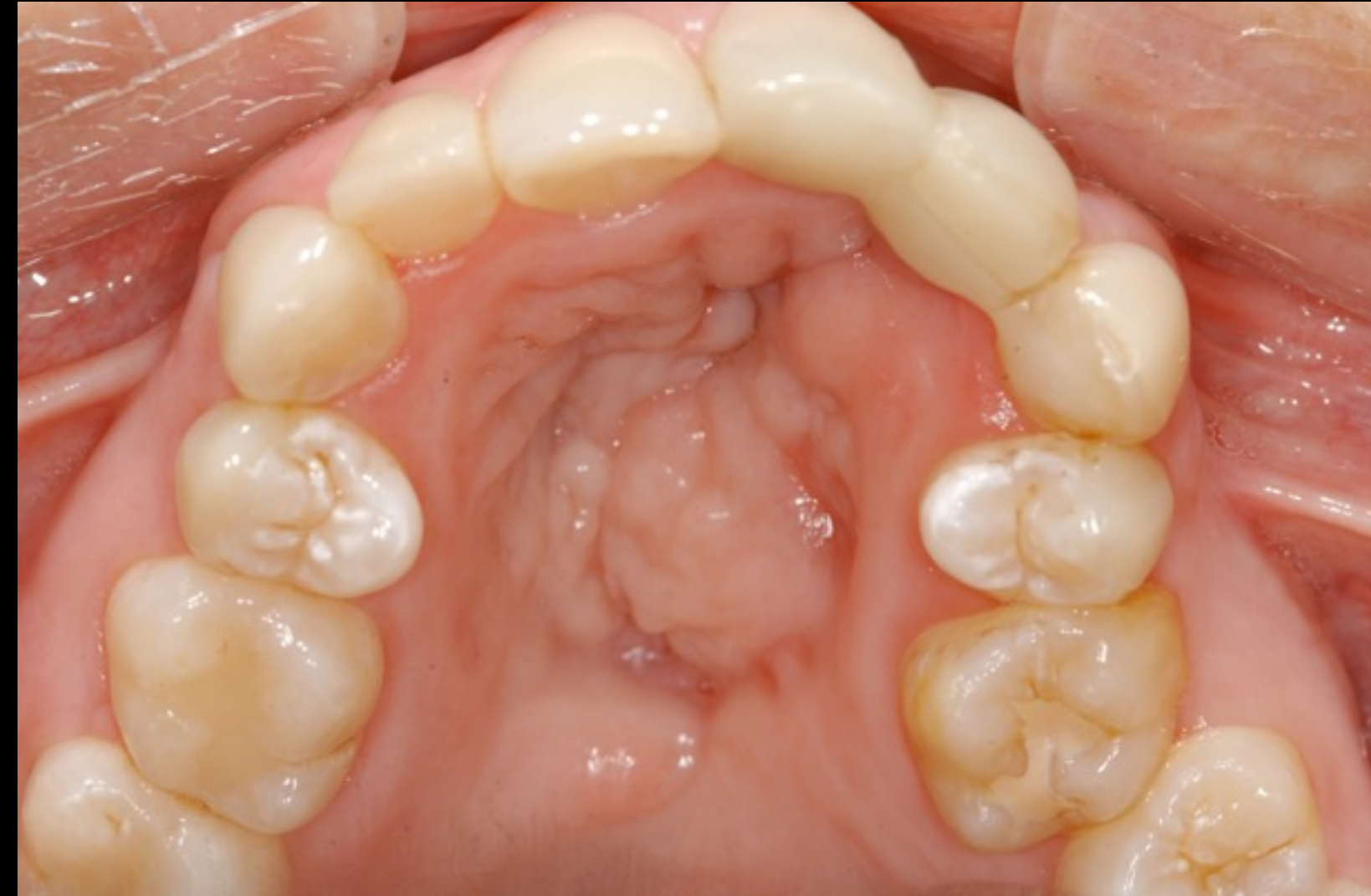
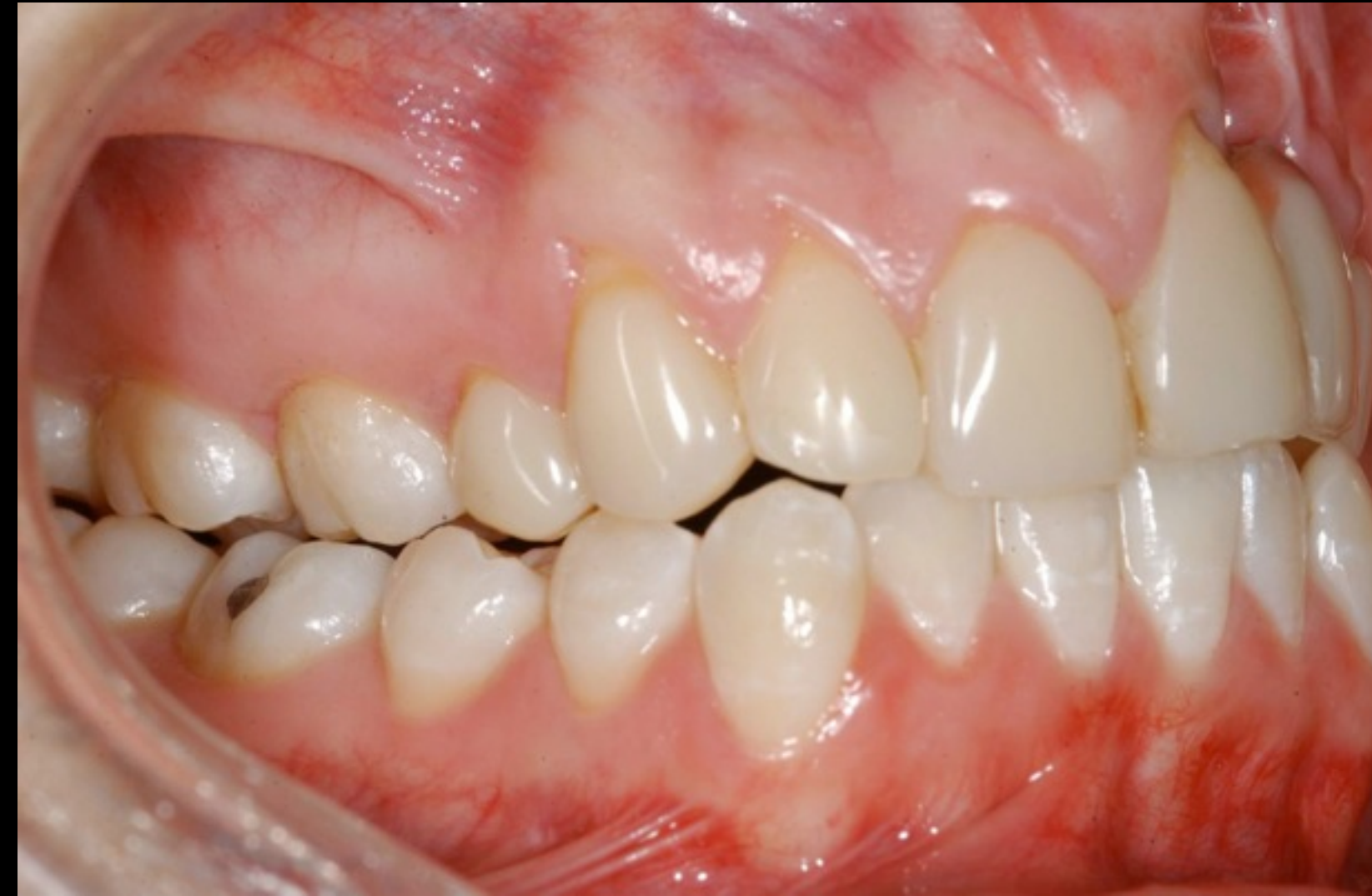Radiographs



# Initial Exam

2010 Perspective



Initial Exam 2010



# SFOT Treatment Plan

Problem

Management

**Dentoalveolar compensations**



**Orthodontic Decompensations**



**Thin crestal/radicular  
dentoalveolar bone phenotype  
Gingival recession**



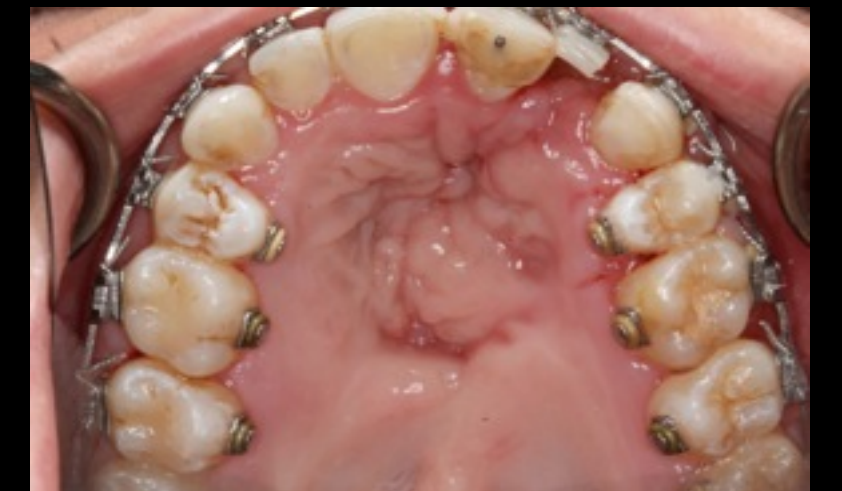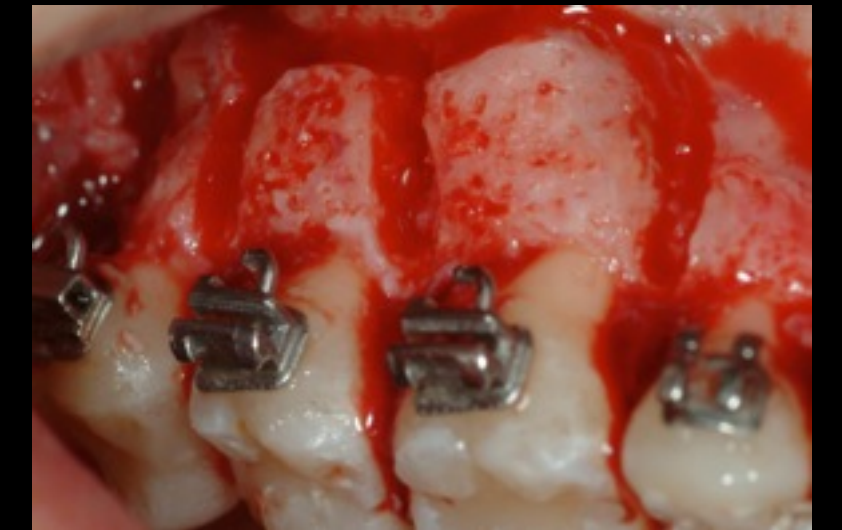**S F O T**



**Skeletal anomaly**



**Cleft palate revision  
surgery**



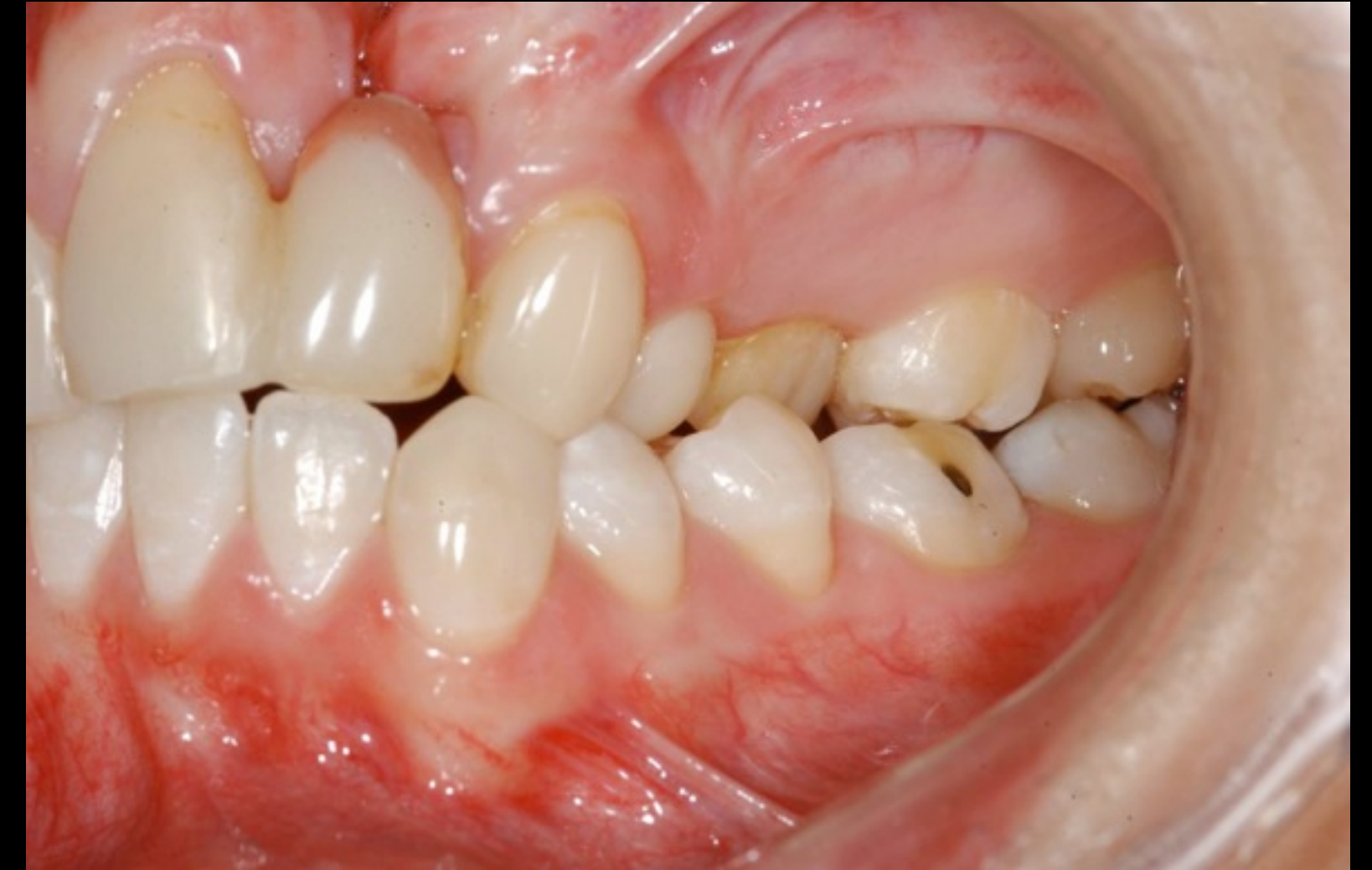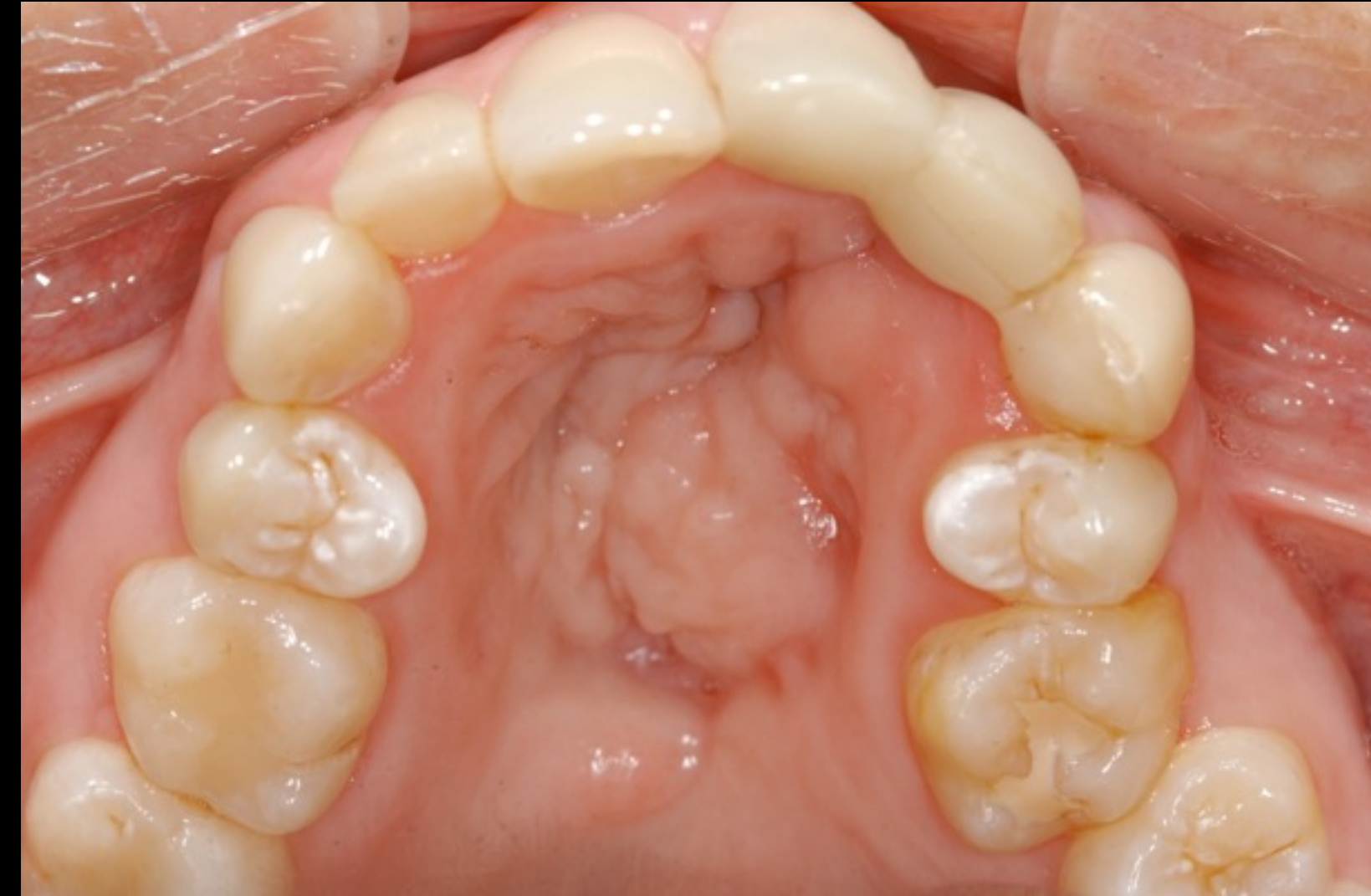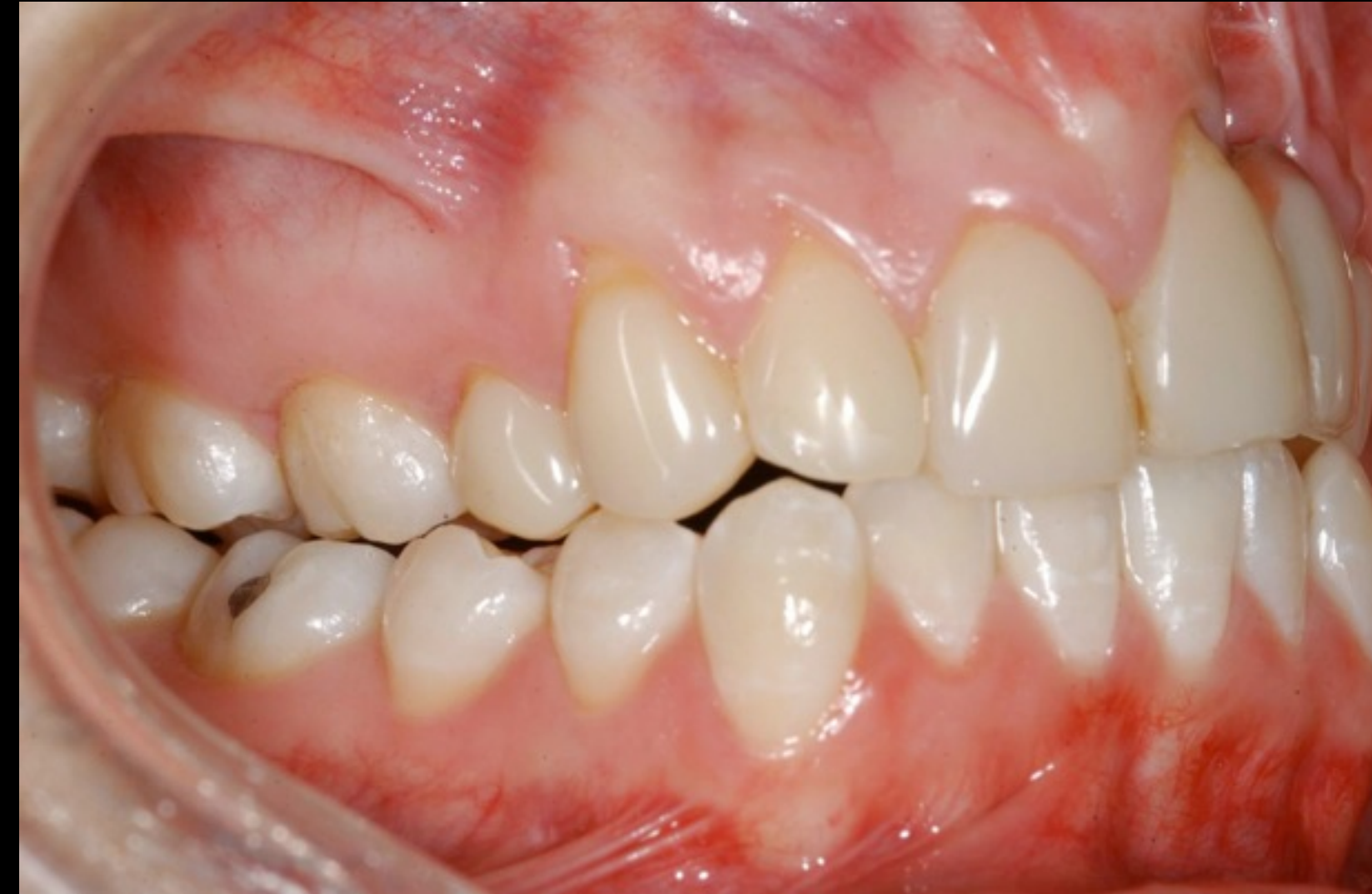*transverse Deficiency*

*Dentoalveolar Bone Deficiency*



# Re - evaluating the problem

*Changing Paradigms*

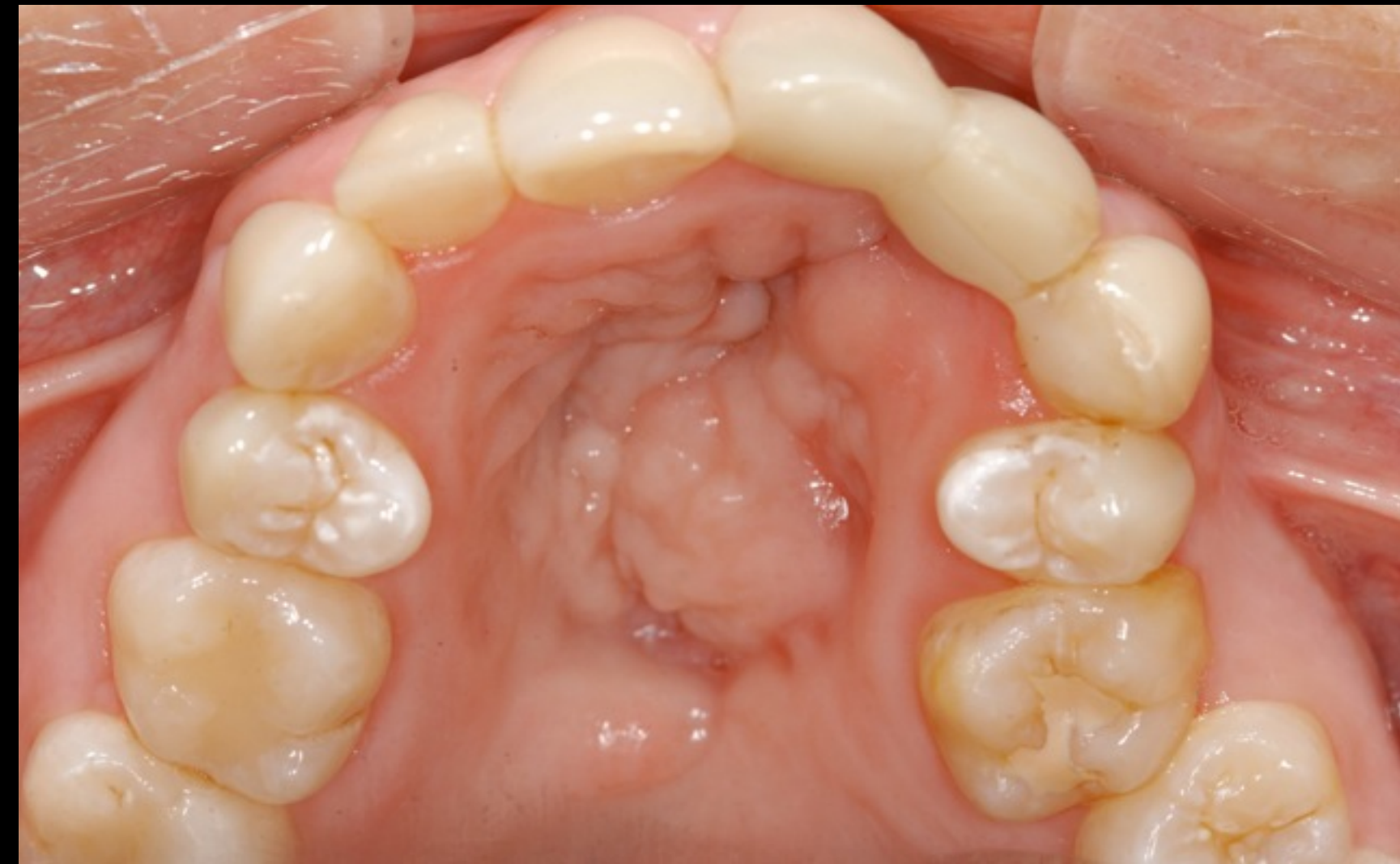

*Alternative Approaches*

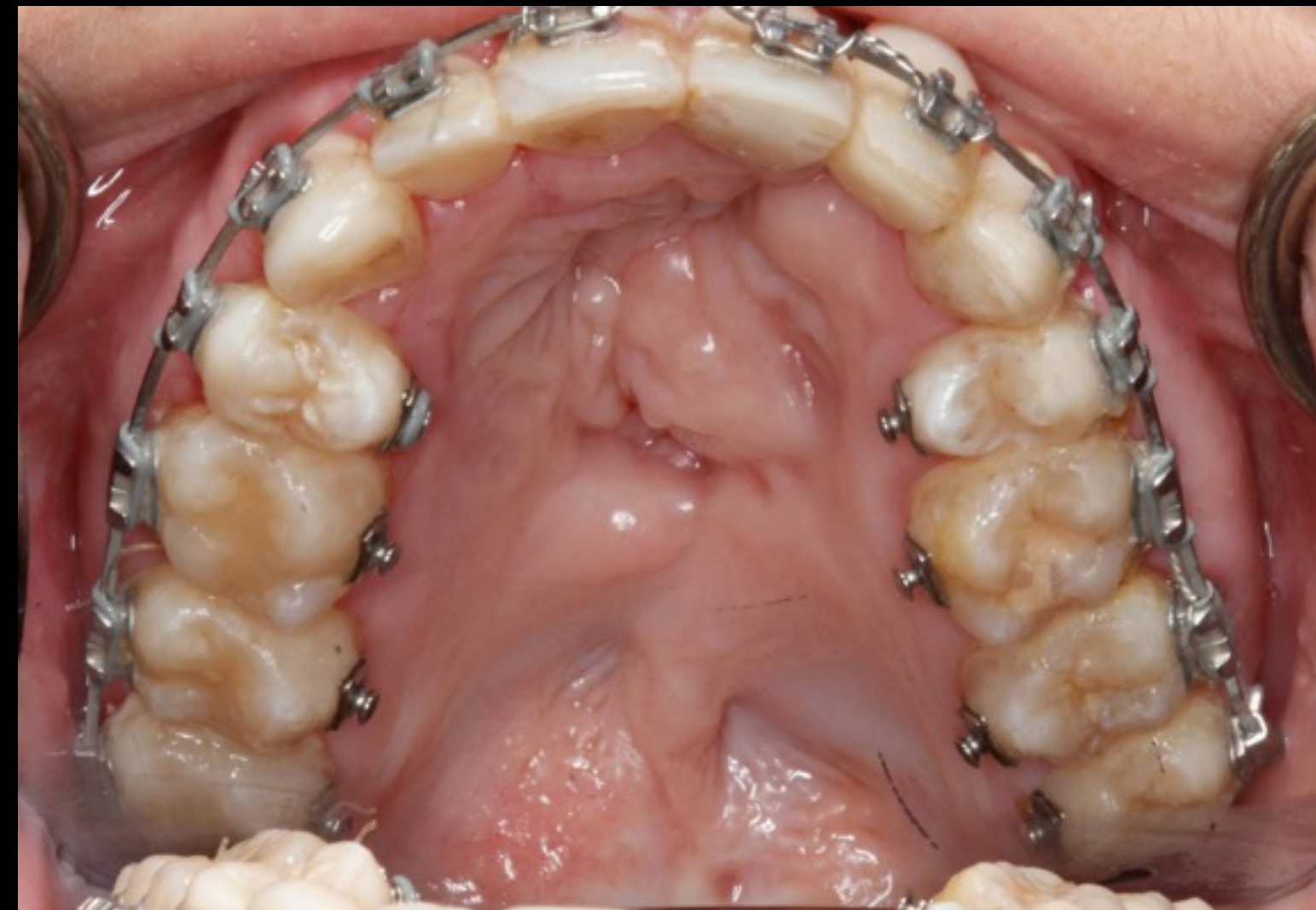

Early Healing Timeline

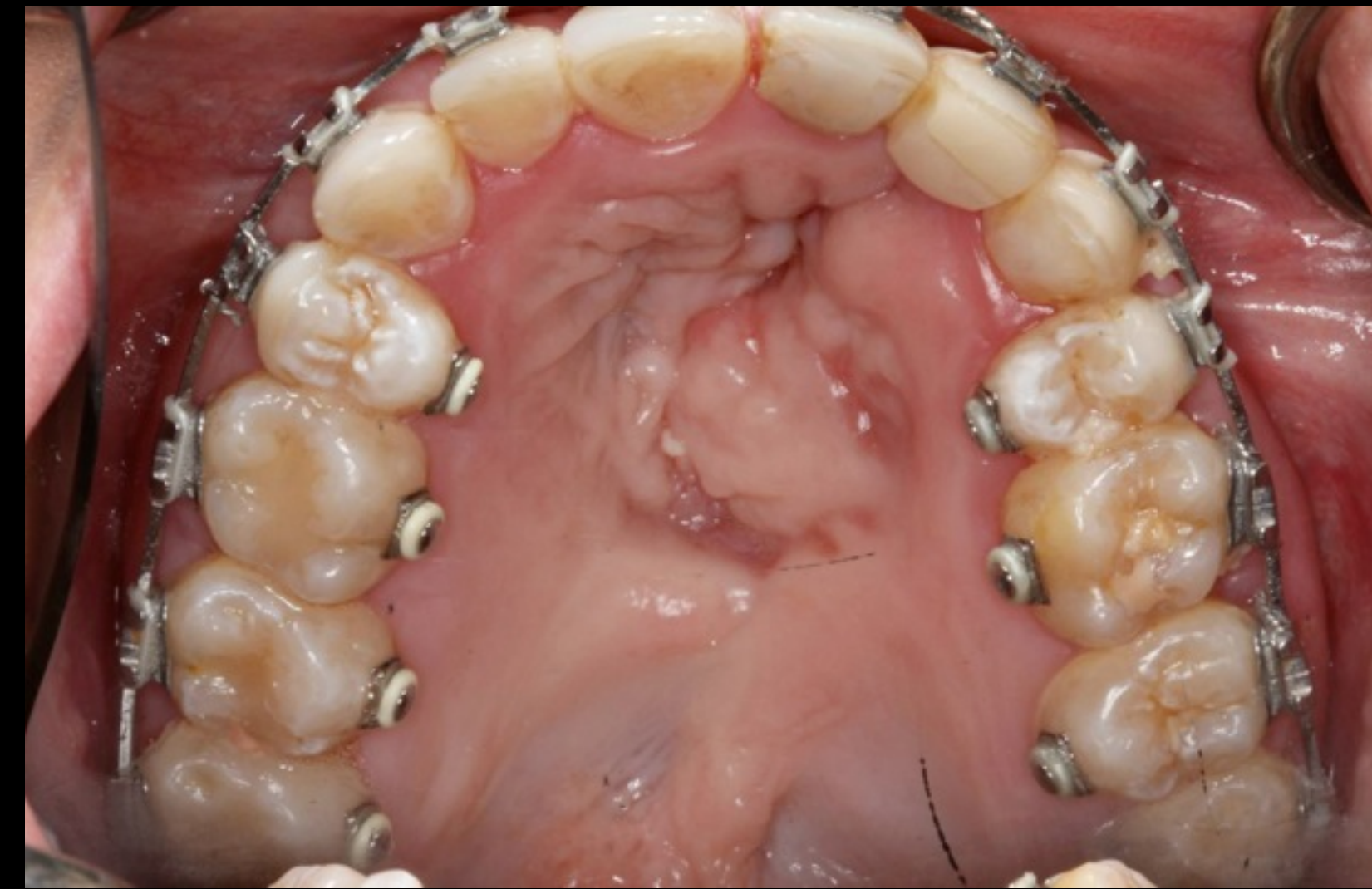Pre Op



2 weeks



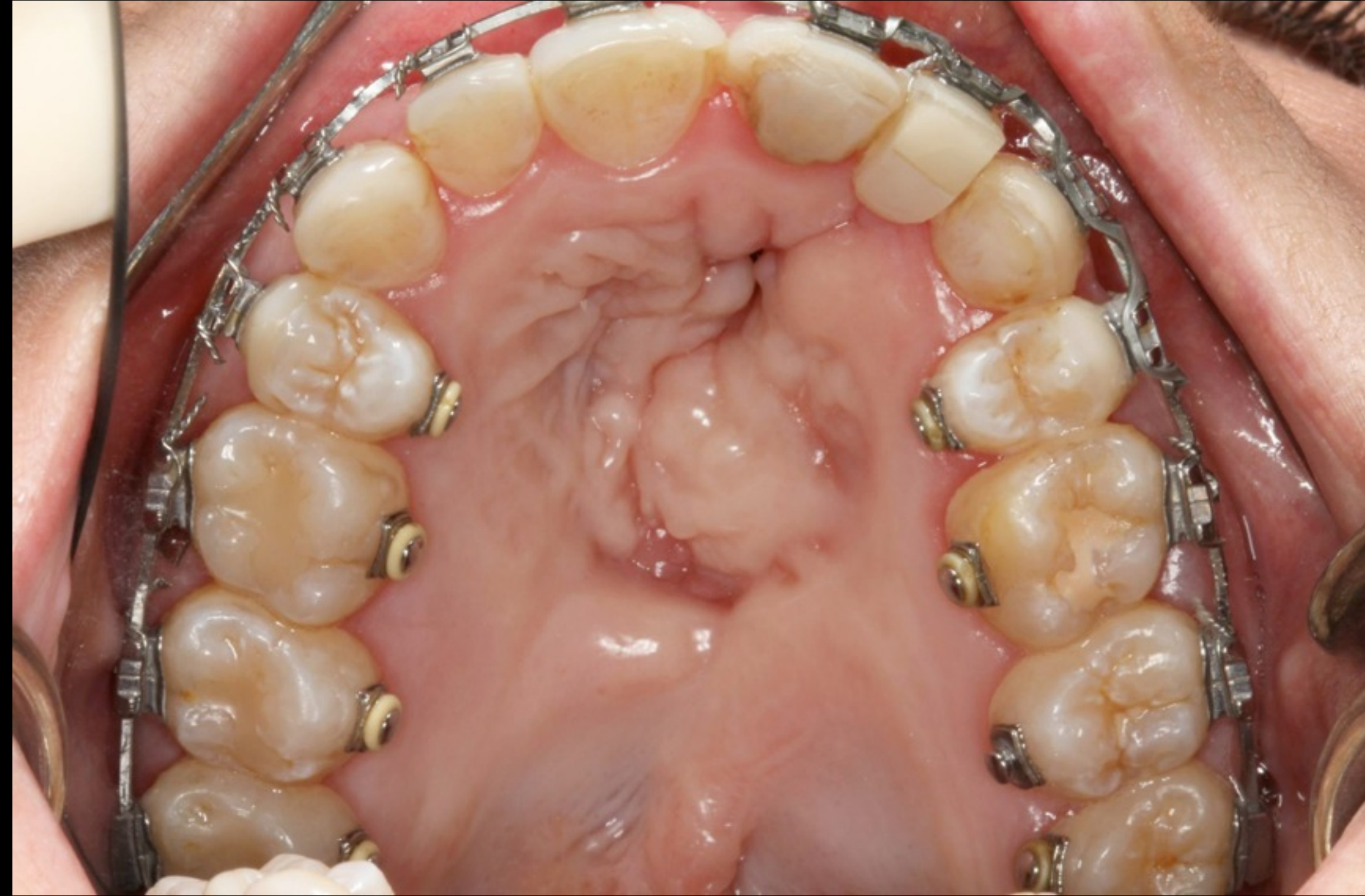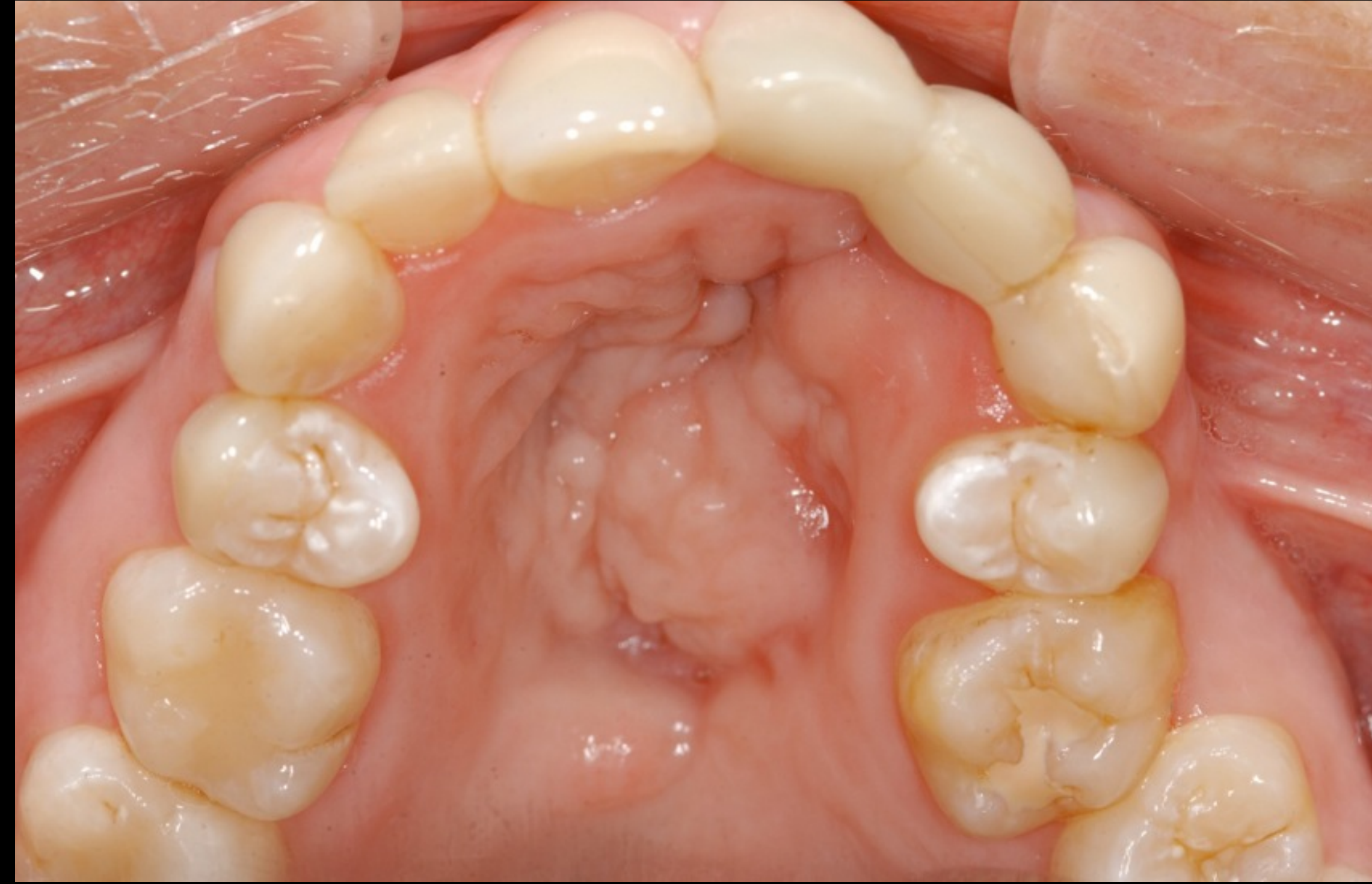8 weeks



RAP



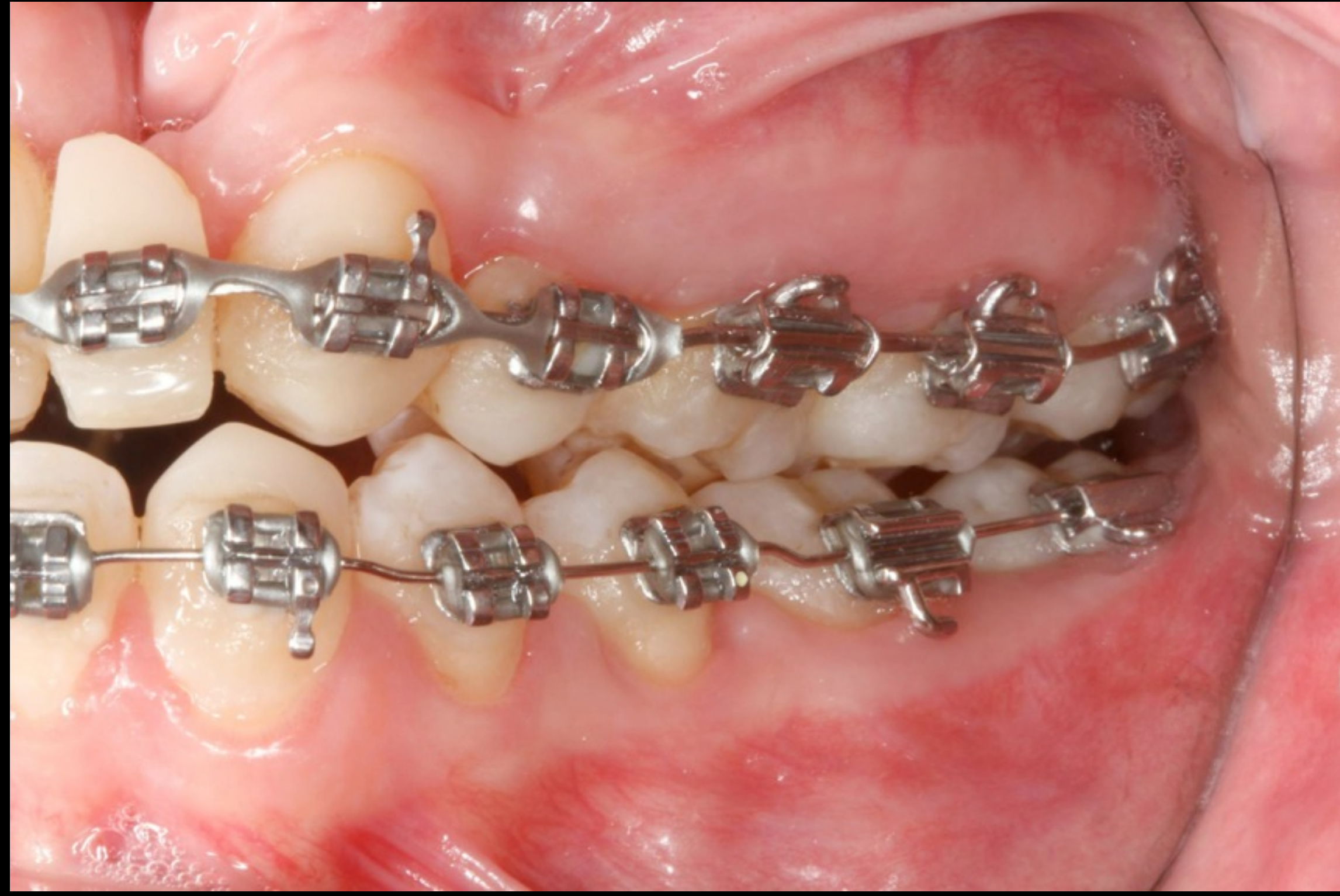
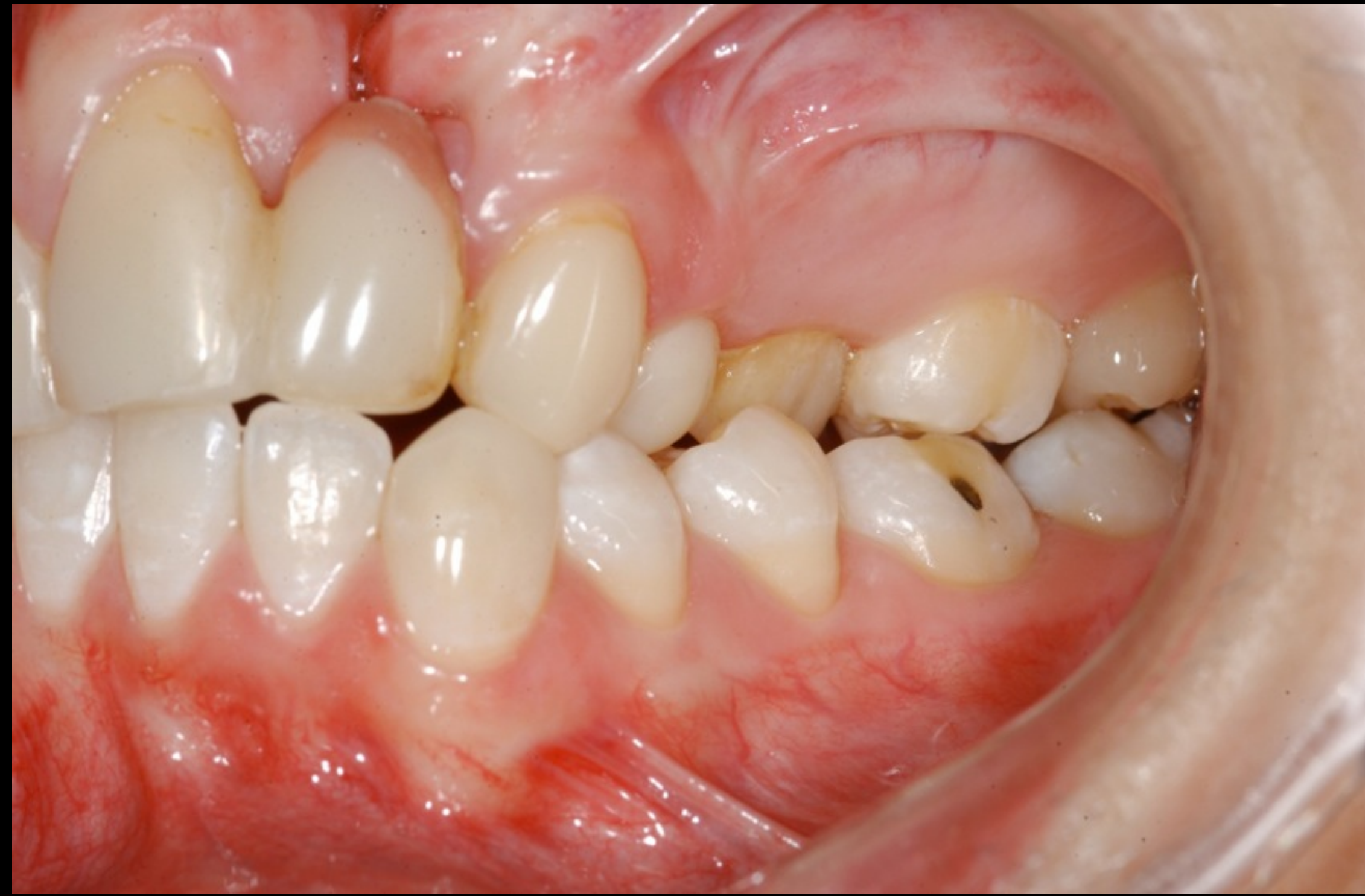Pre Op SFOT



4 month post SFOT



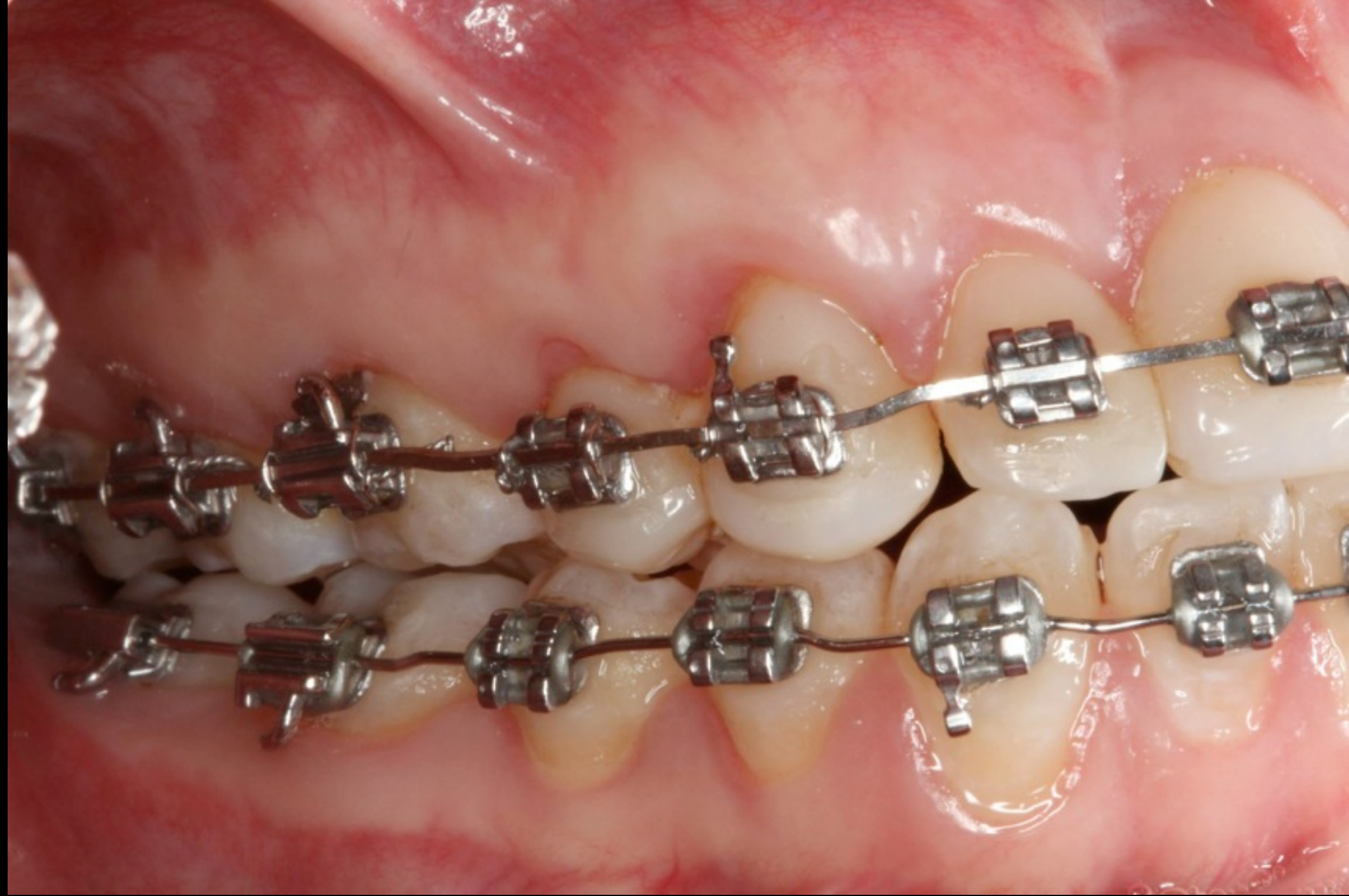
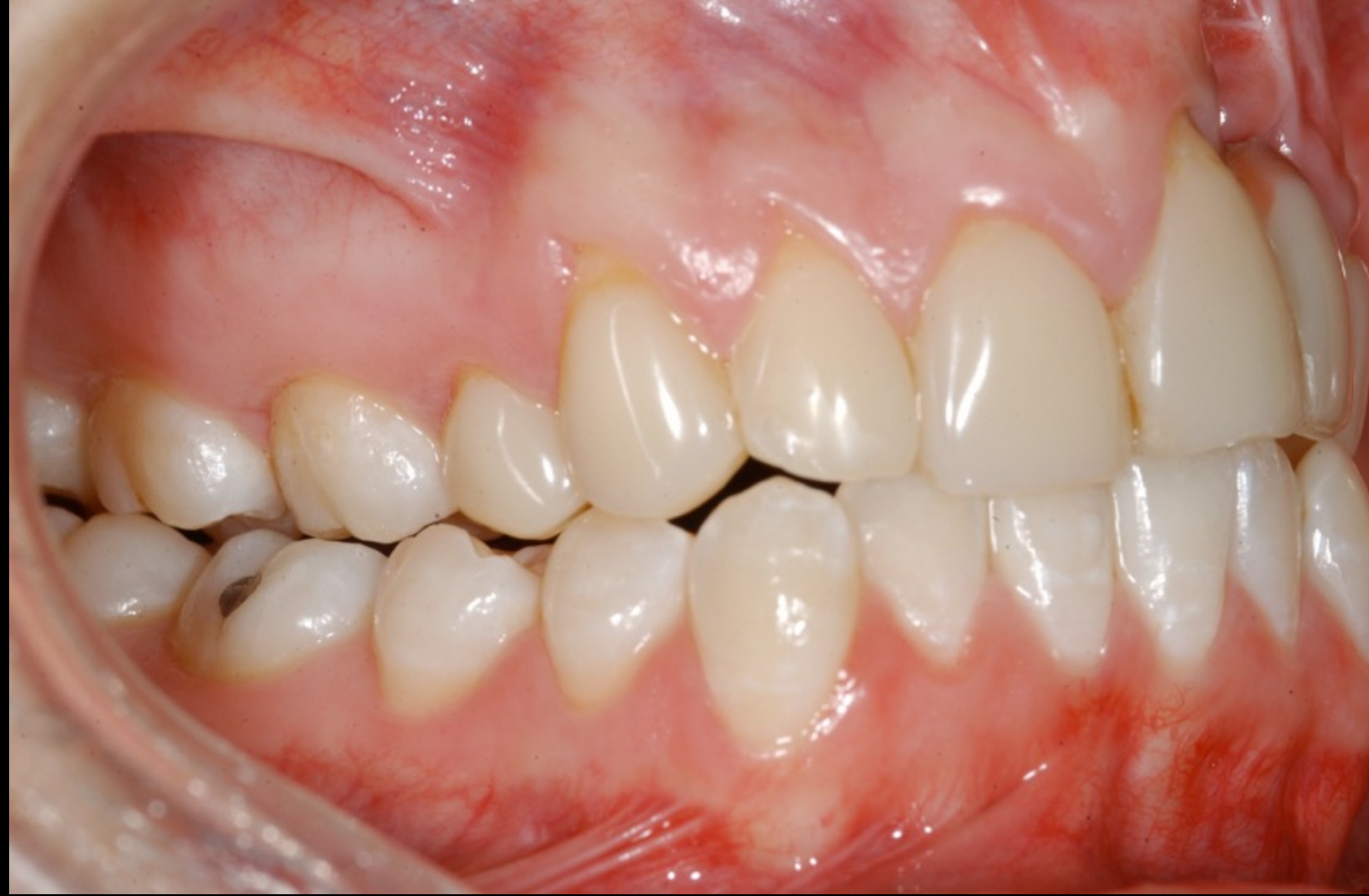Pre Op SFOT



4 month post SFOT



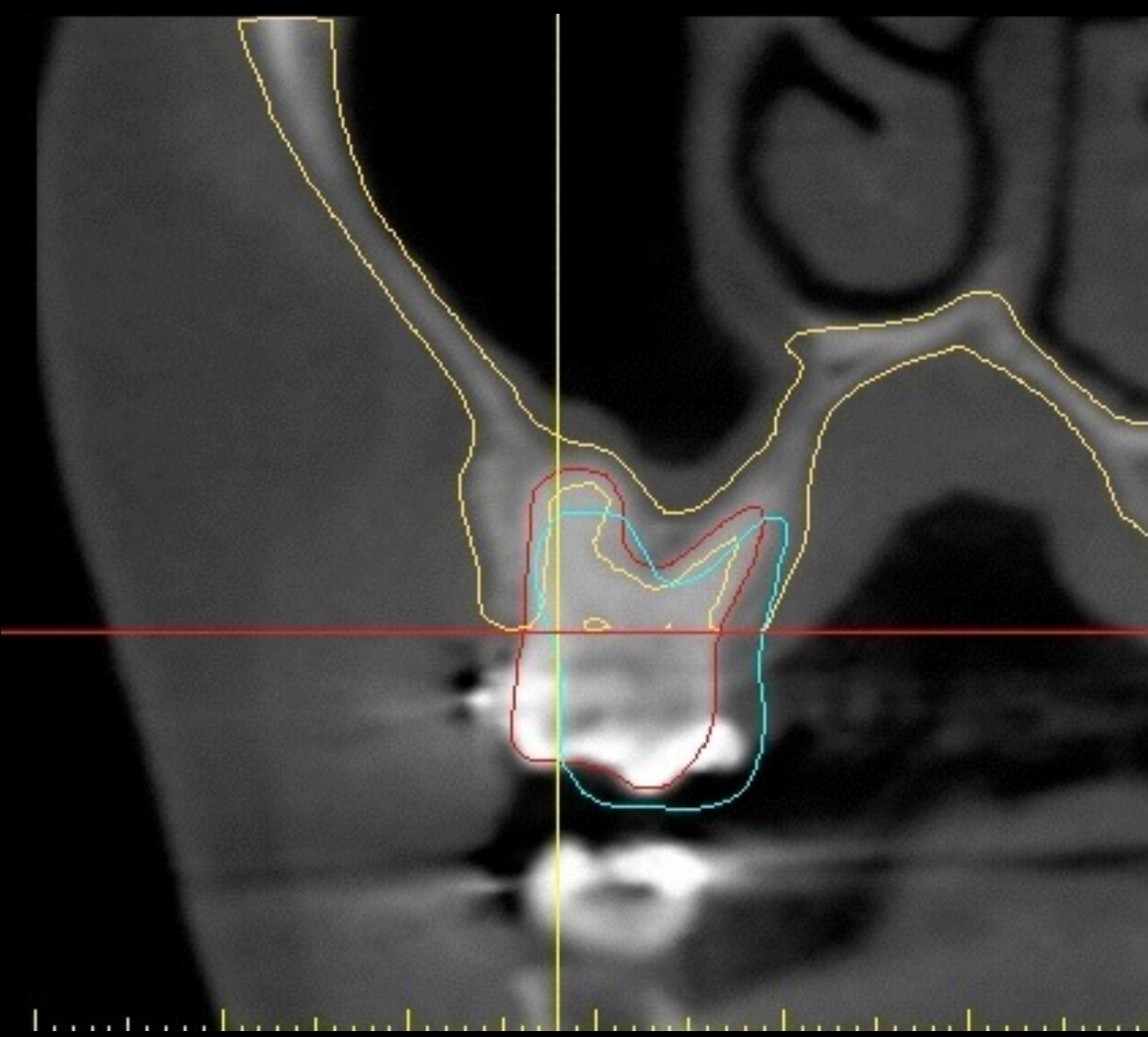
Pre Op SFOT



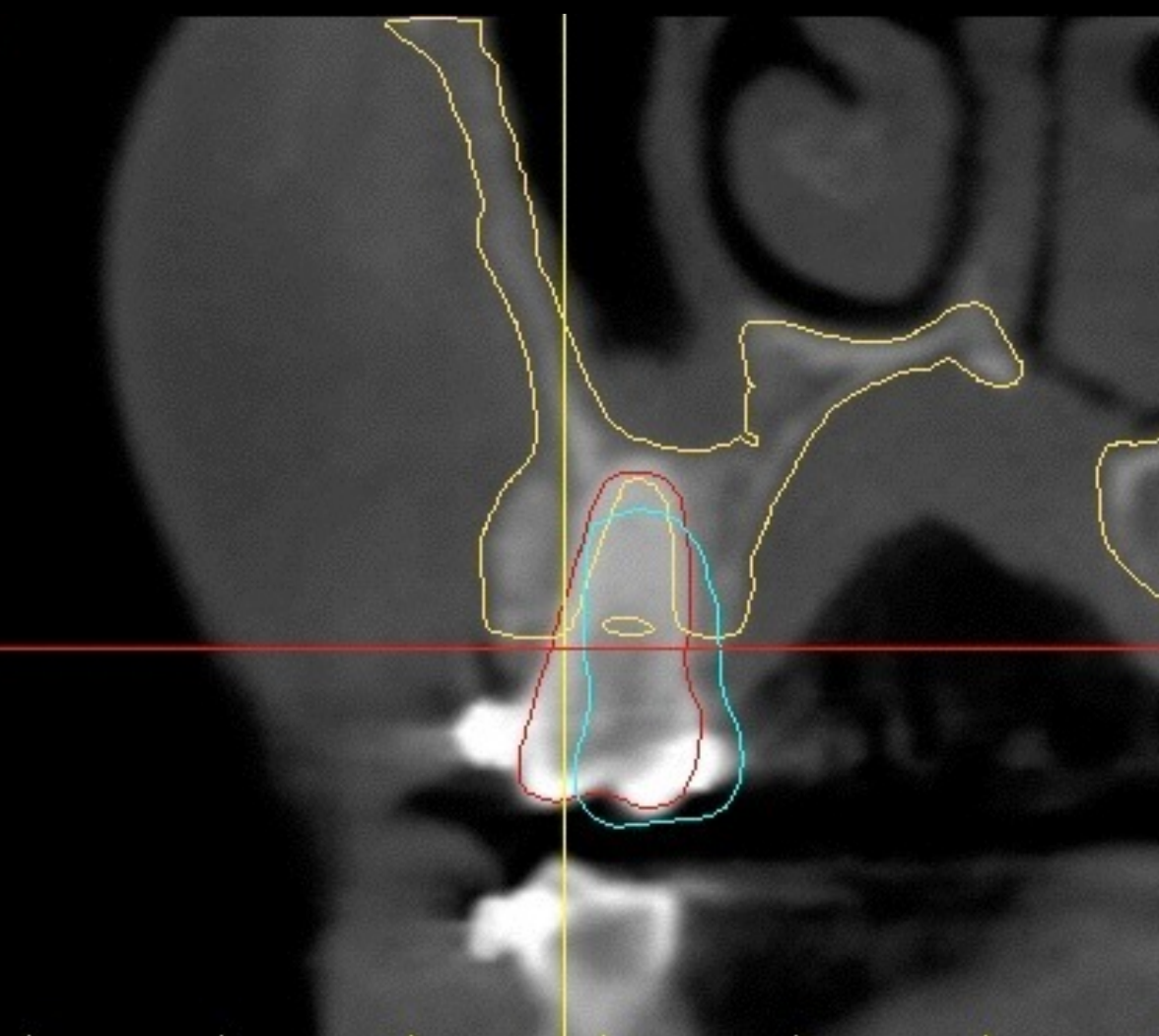
4 month post SFOT



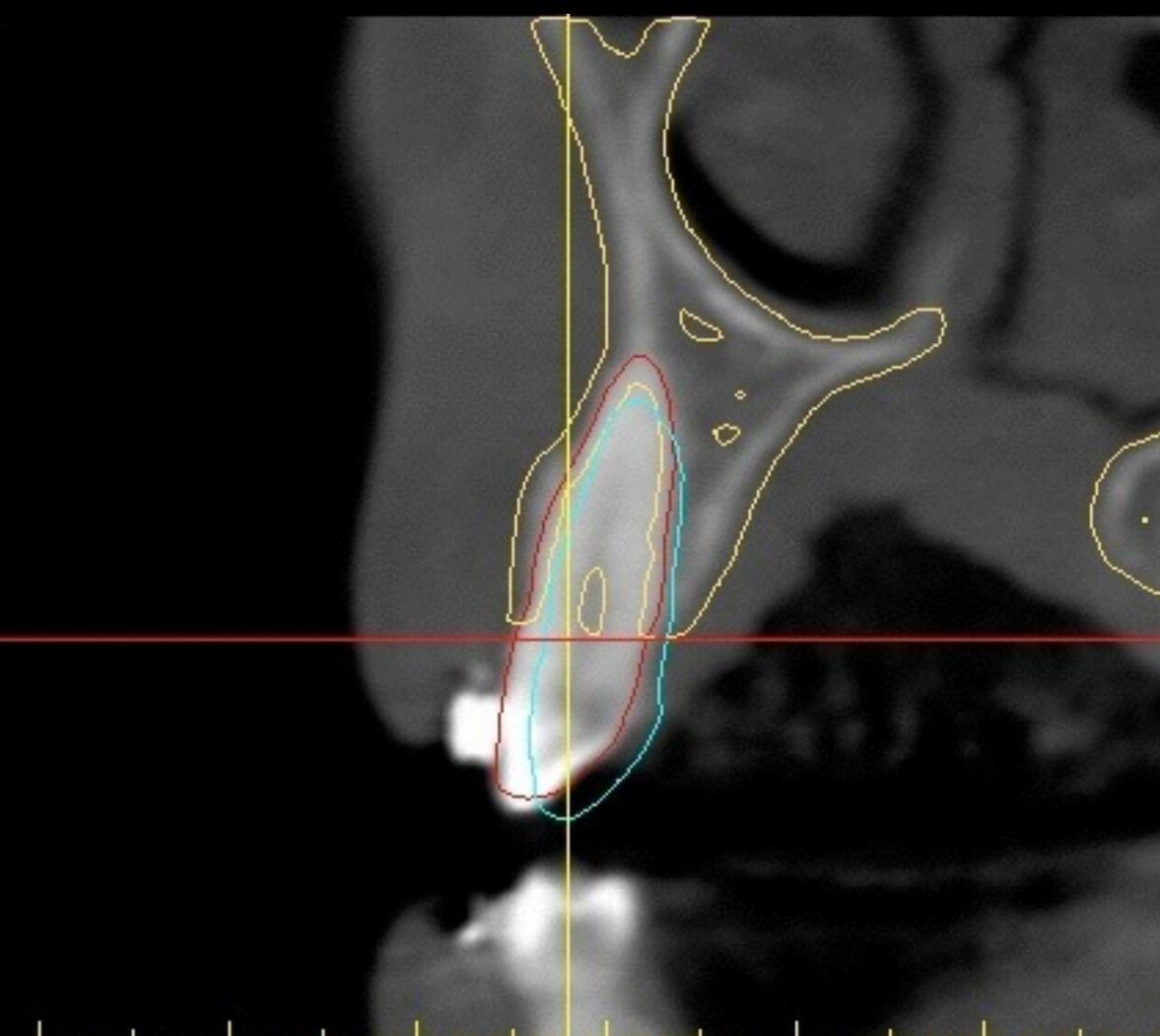
# Matched Pre & Post SFOT CBCT scans for 3D validation at 4 months



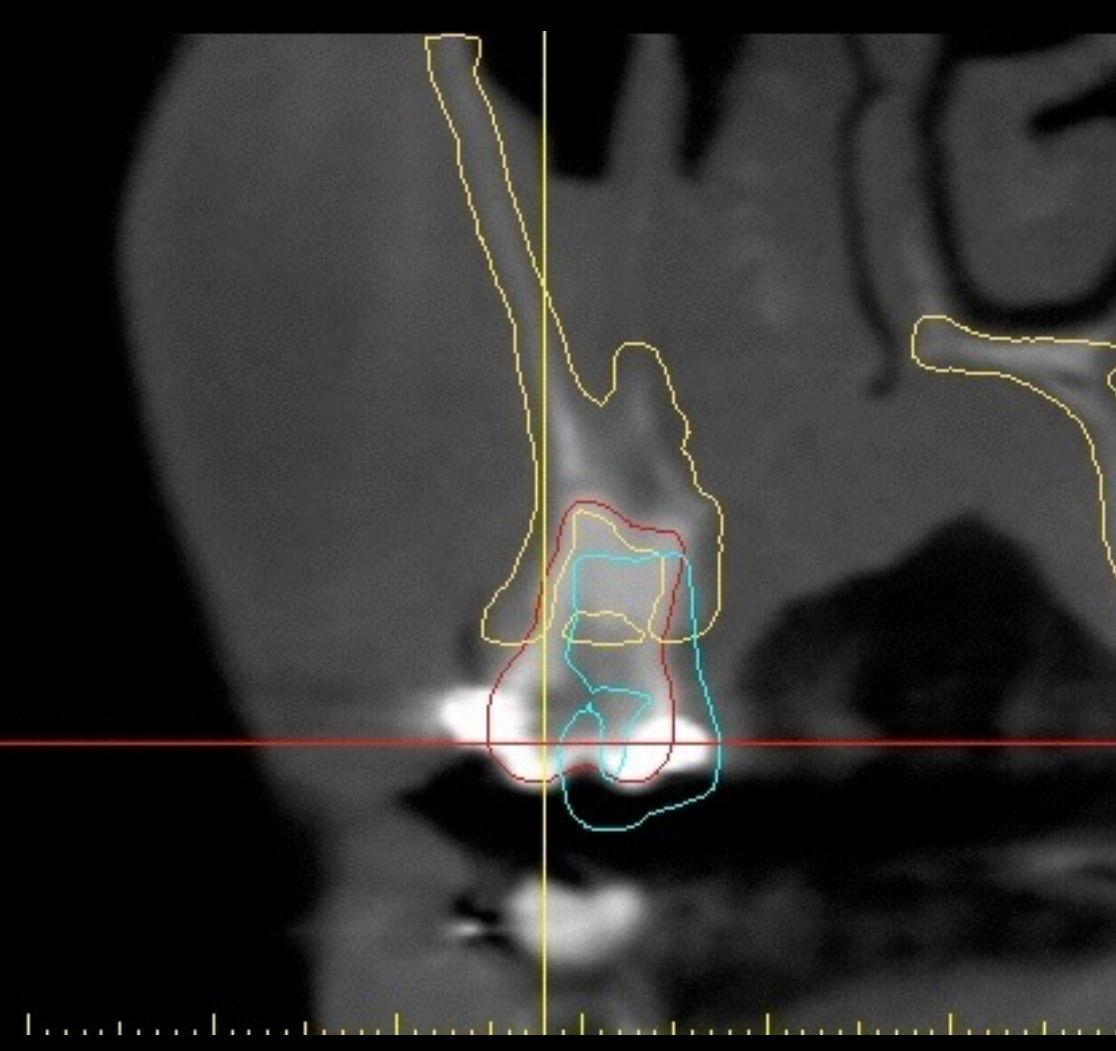
#3



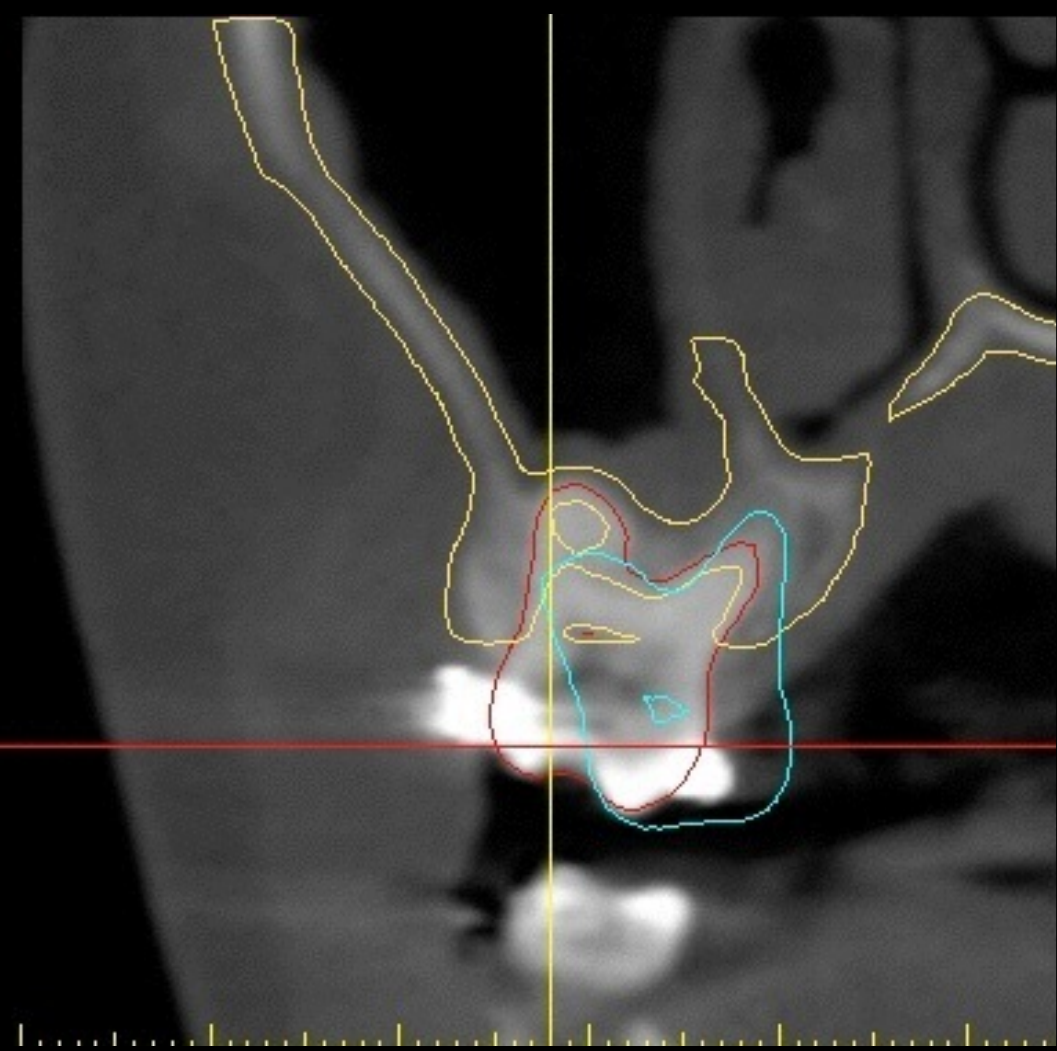#4



#6



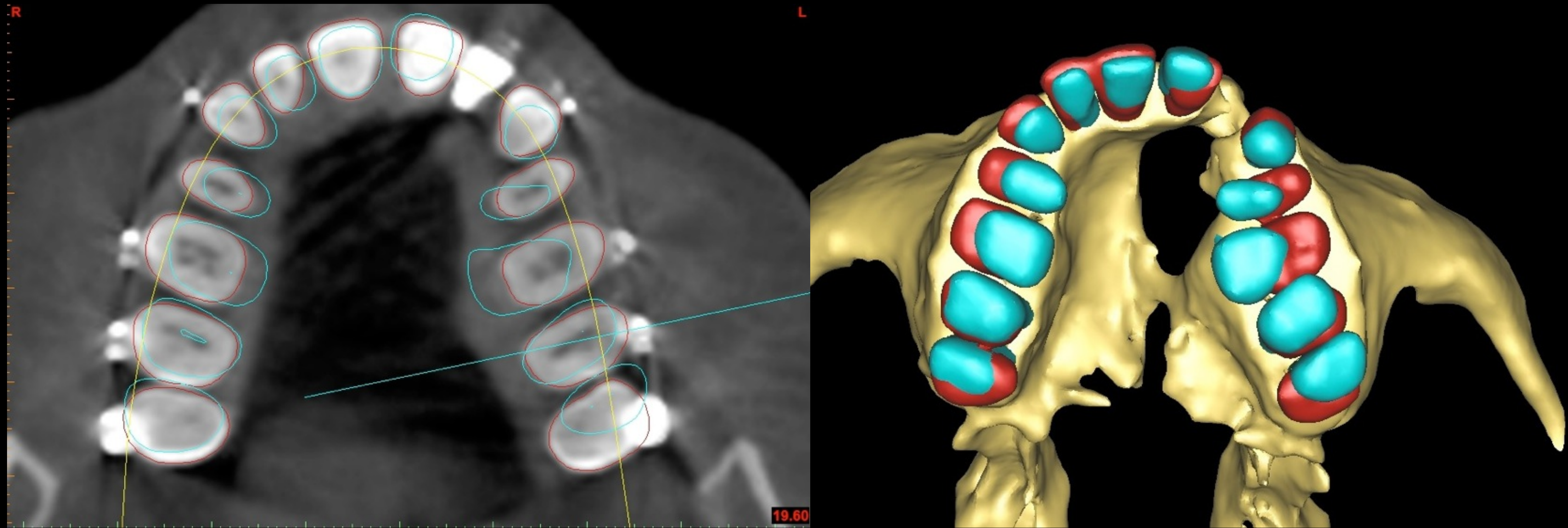
#13



#14

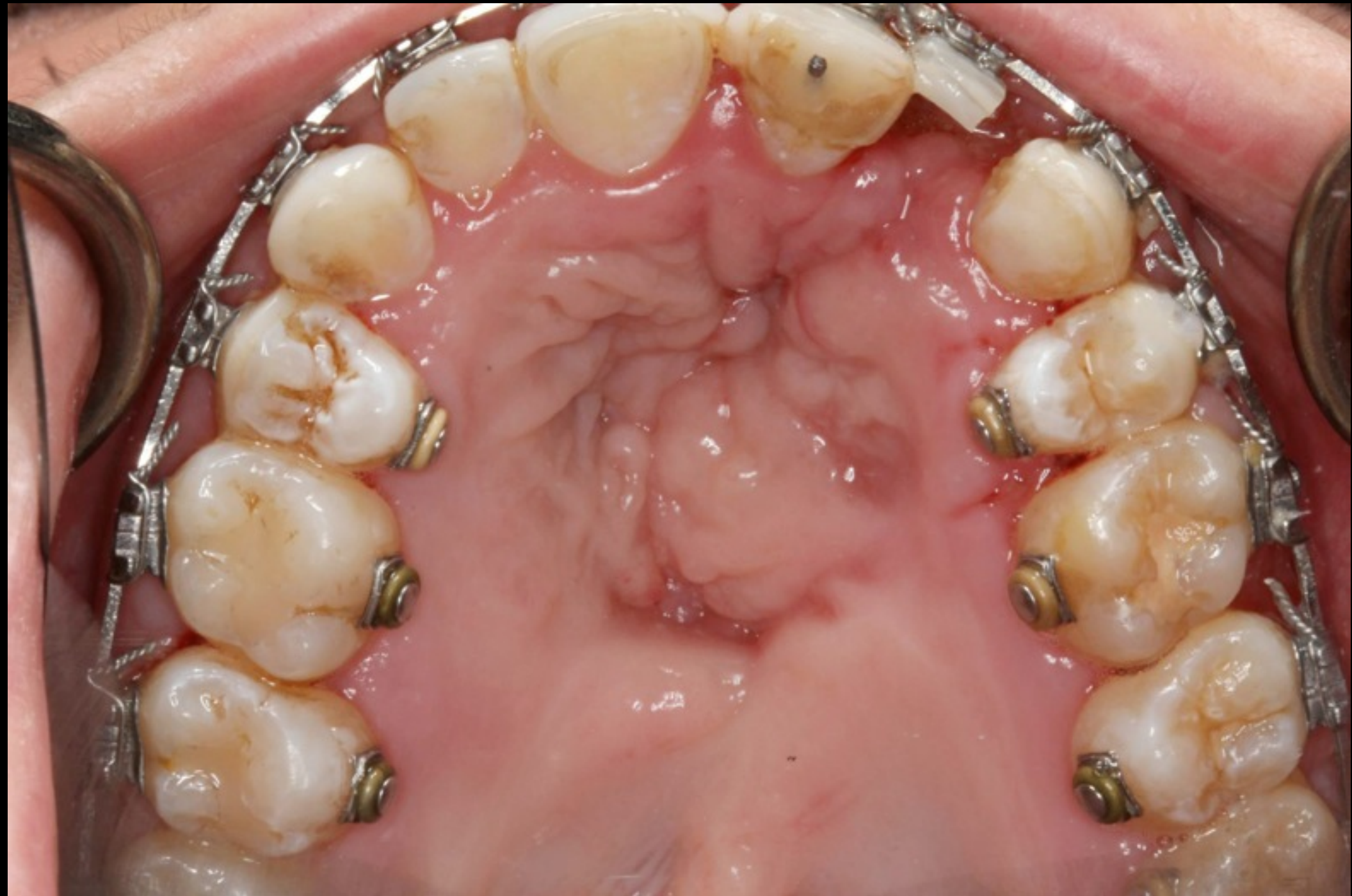
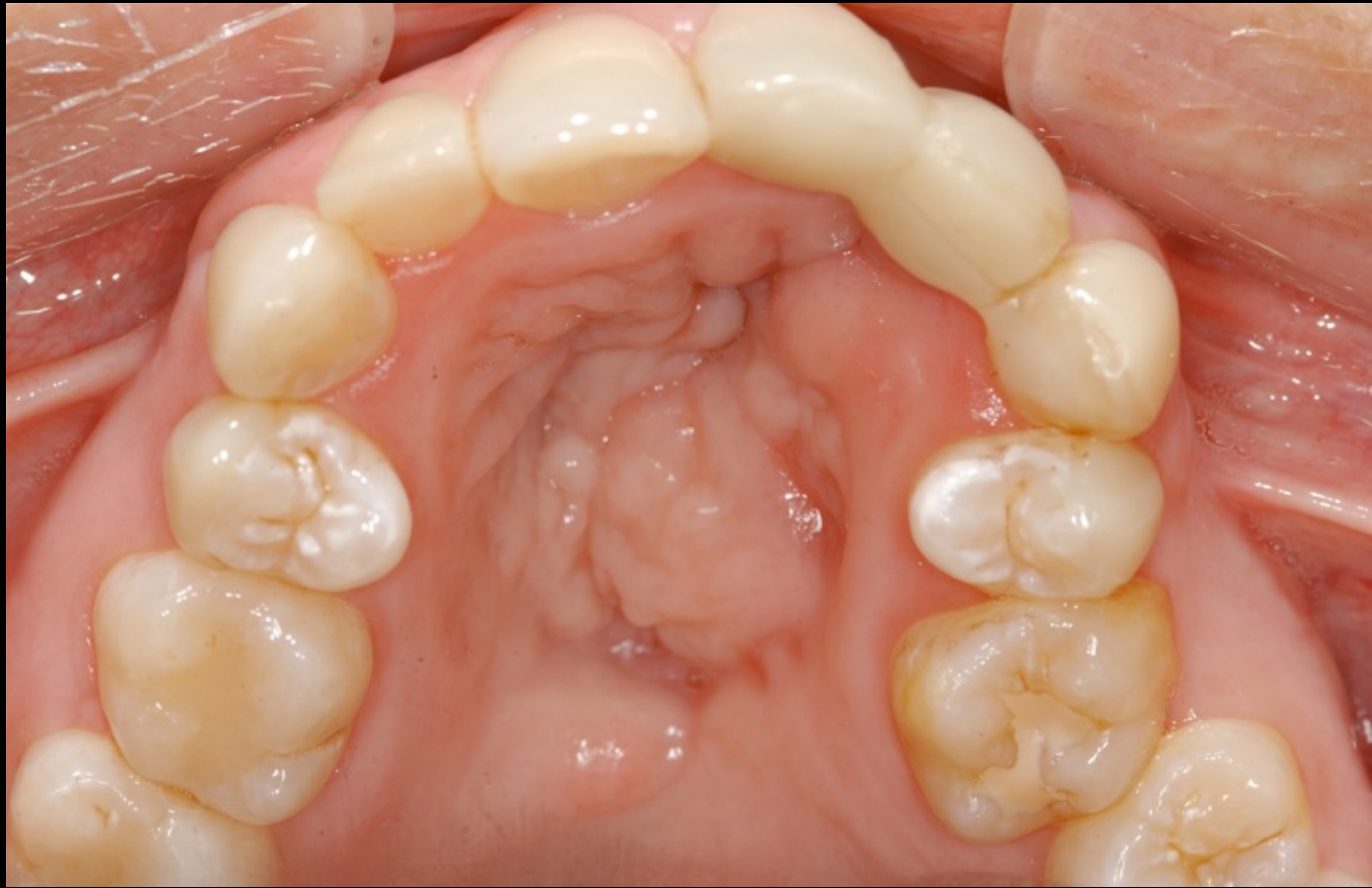
# Matched Pre & Post SFOT CBCT scans for 3D validation at 4 months





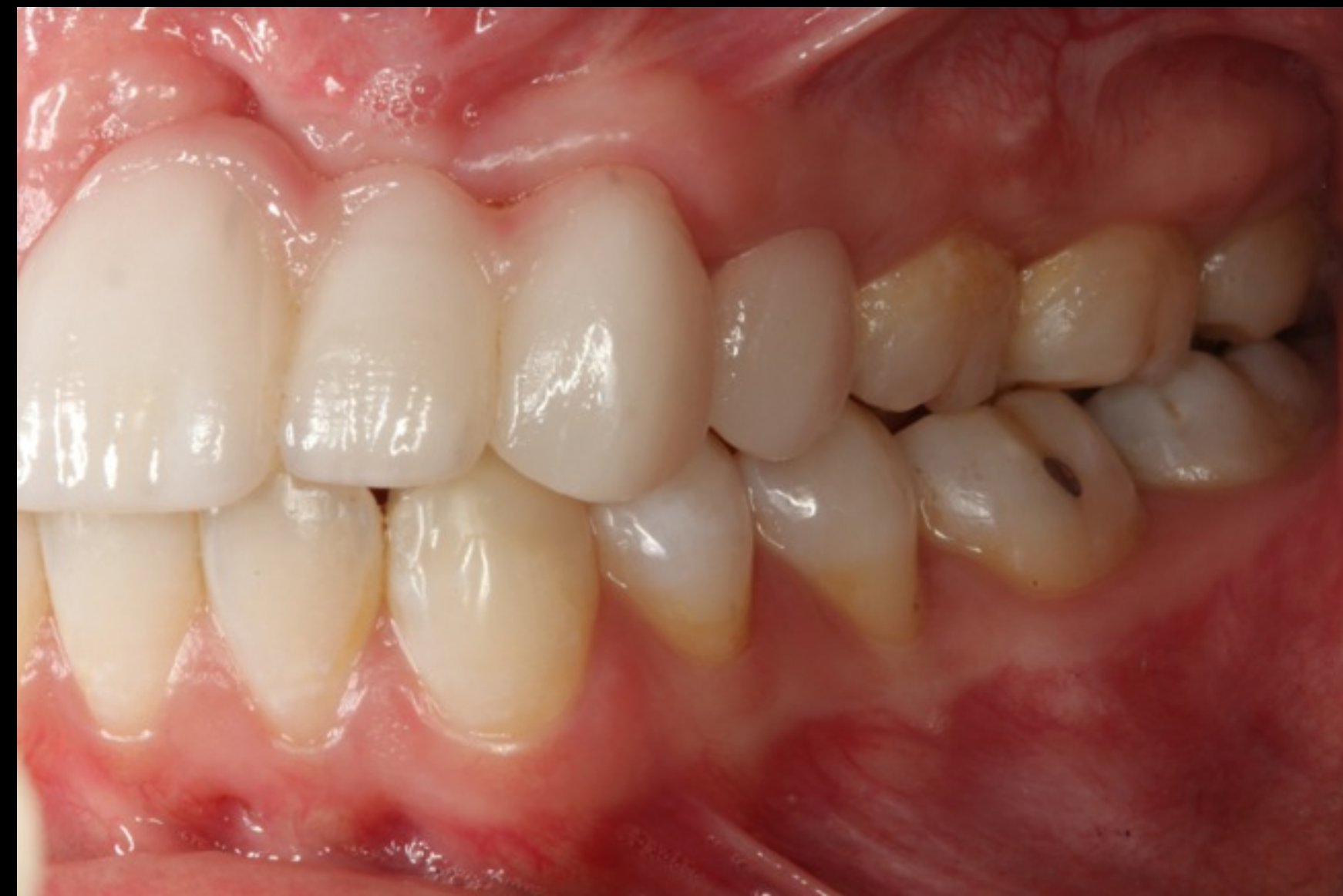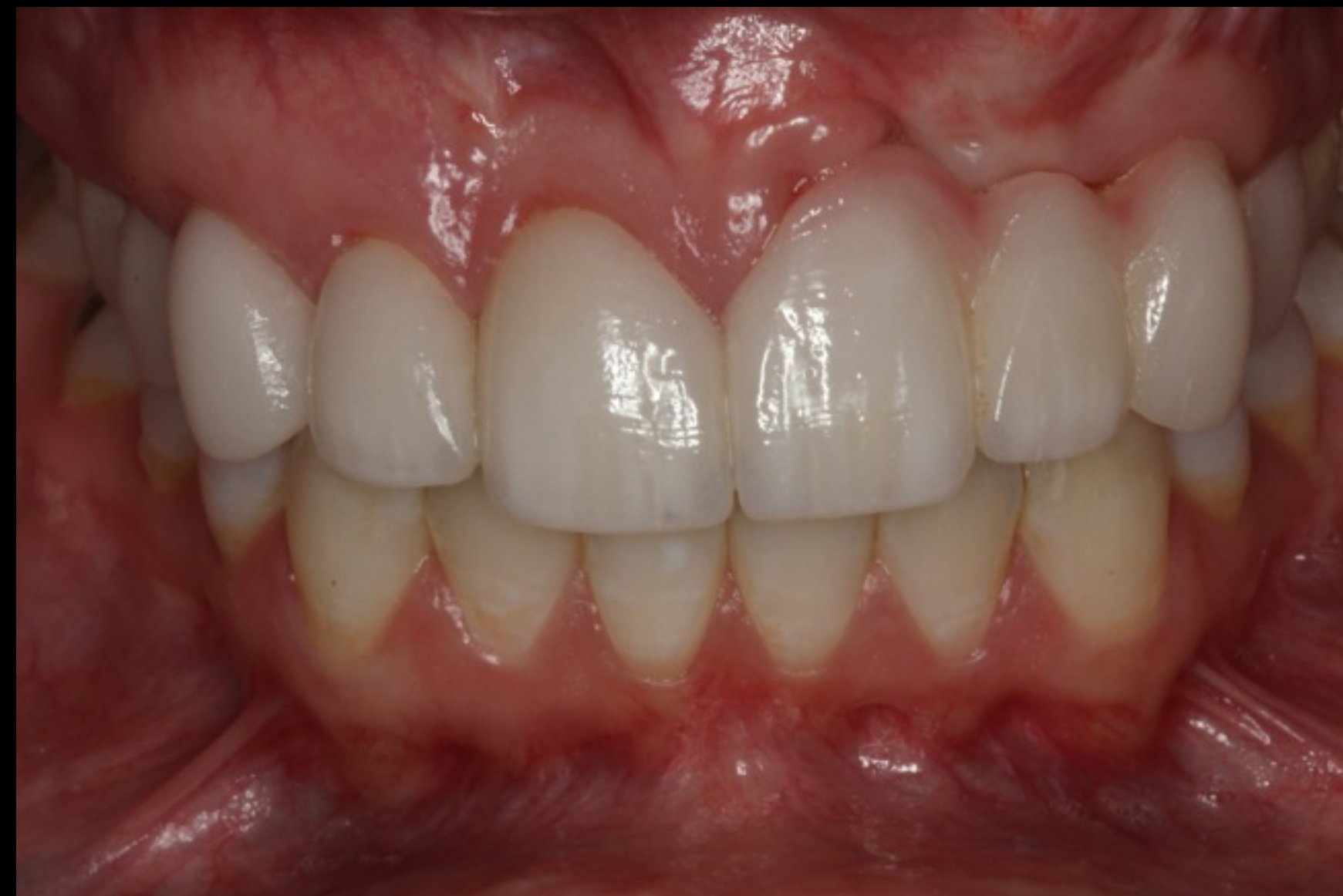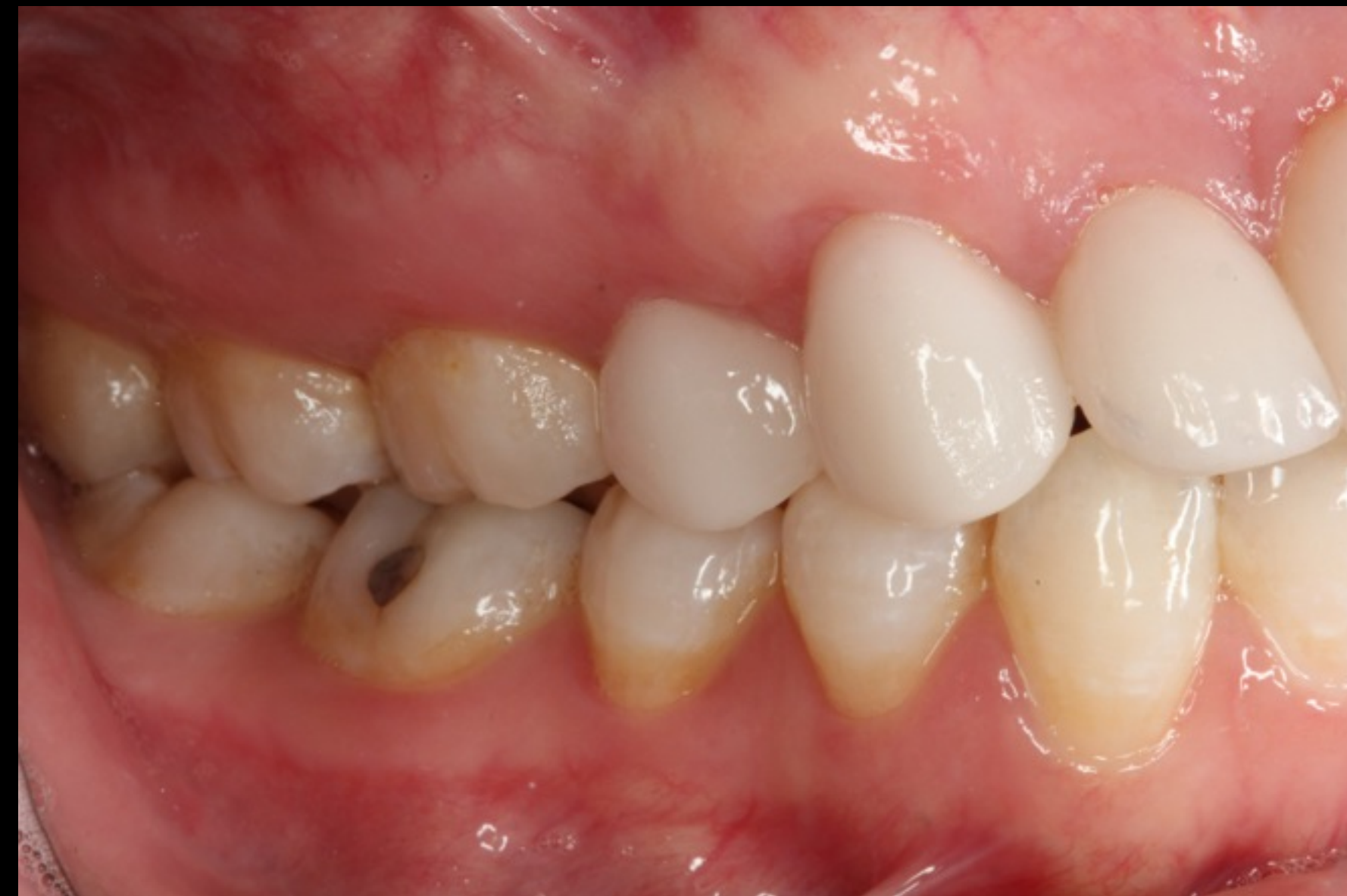*Pre Op Occlusal*



*13 Months Post SFOOT - Max  
1 month post cleft repair*



06.30.2013



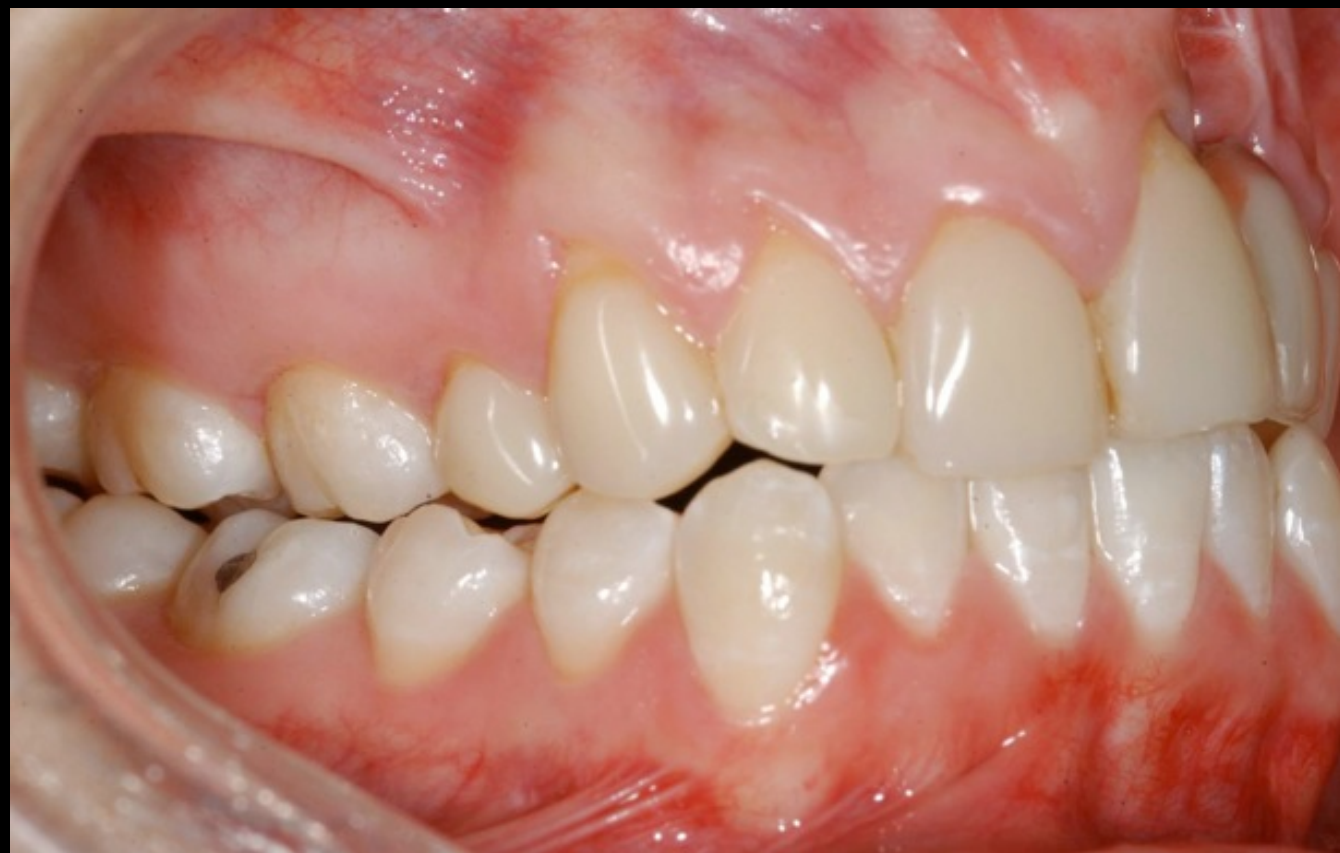*Final Outcome*

*Final Outcome*

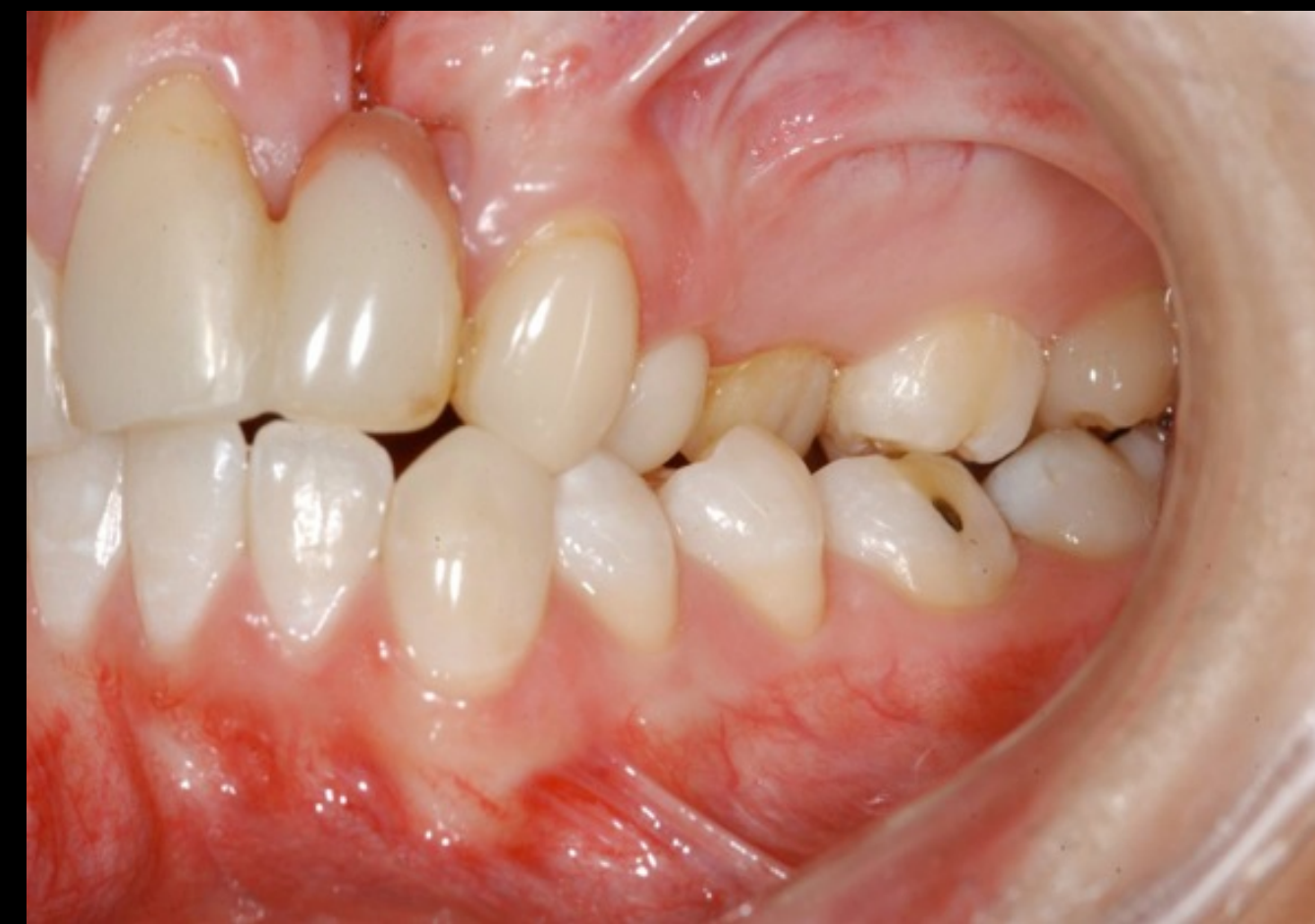
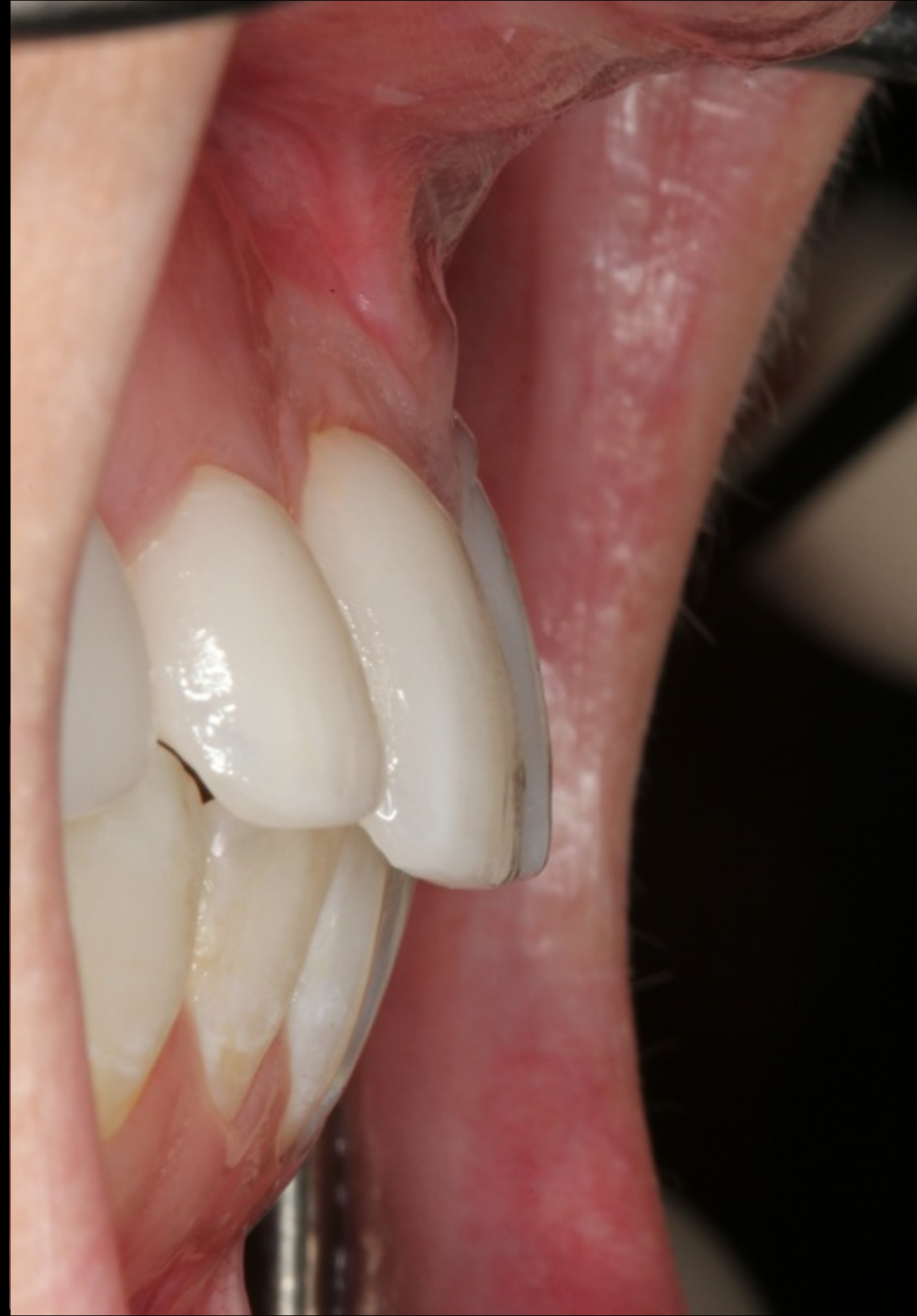
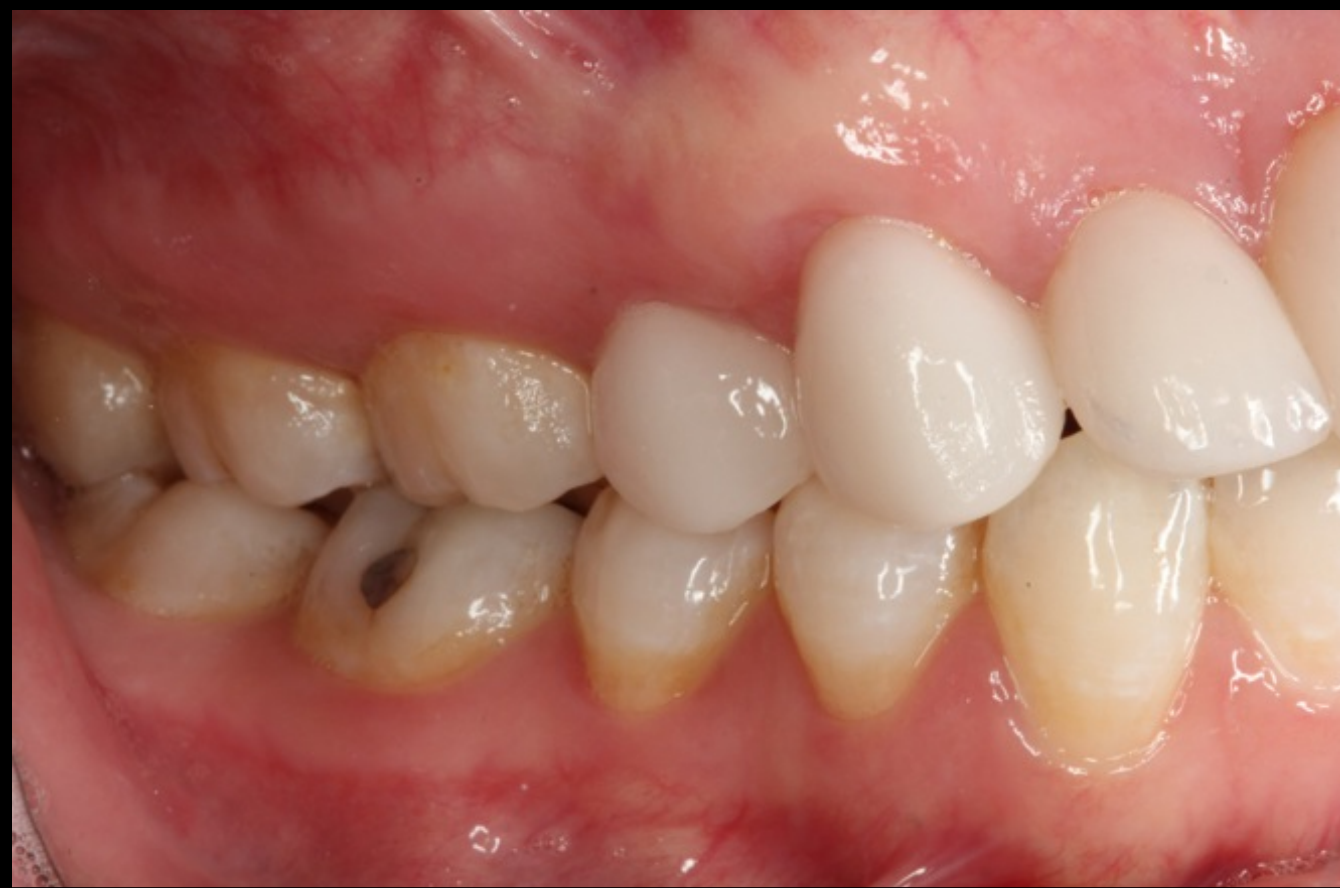*Final Outcome*

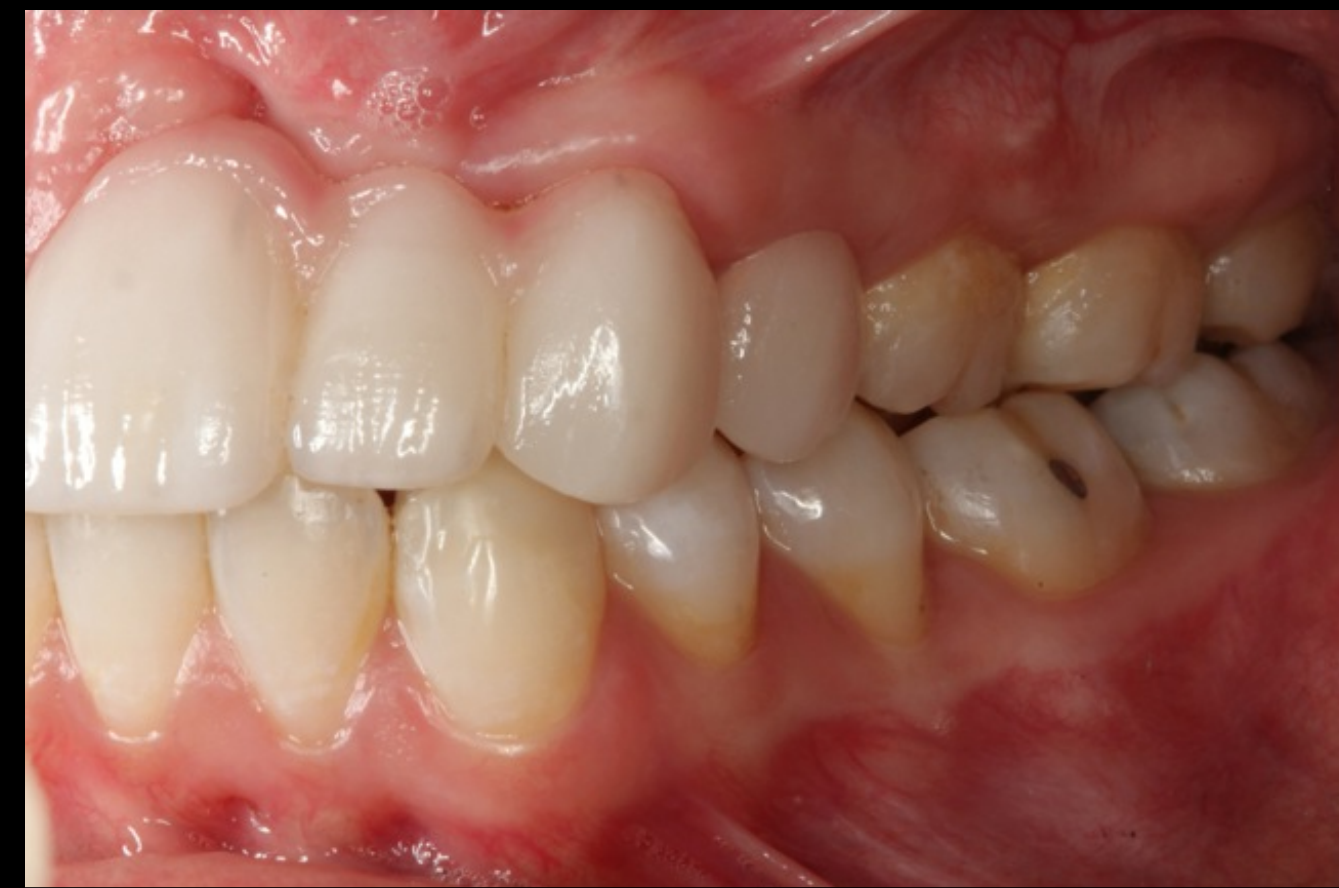**Pre**  
**02.2010**



**Post**  
**06.2013**



**Pre**  
**02.2010**



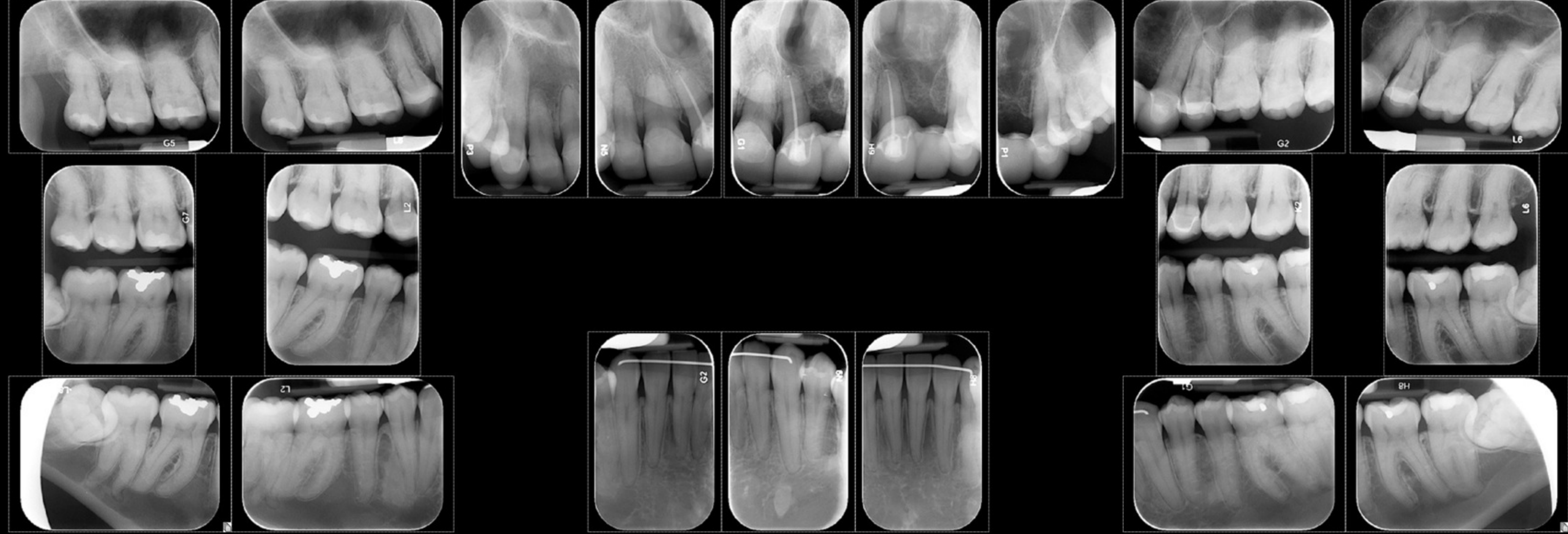
**Post**  
**06.2013**

*Final Outcome*



*Final Radiographs*

*June 2013*

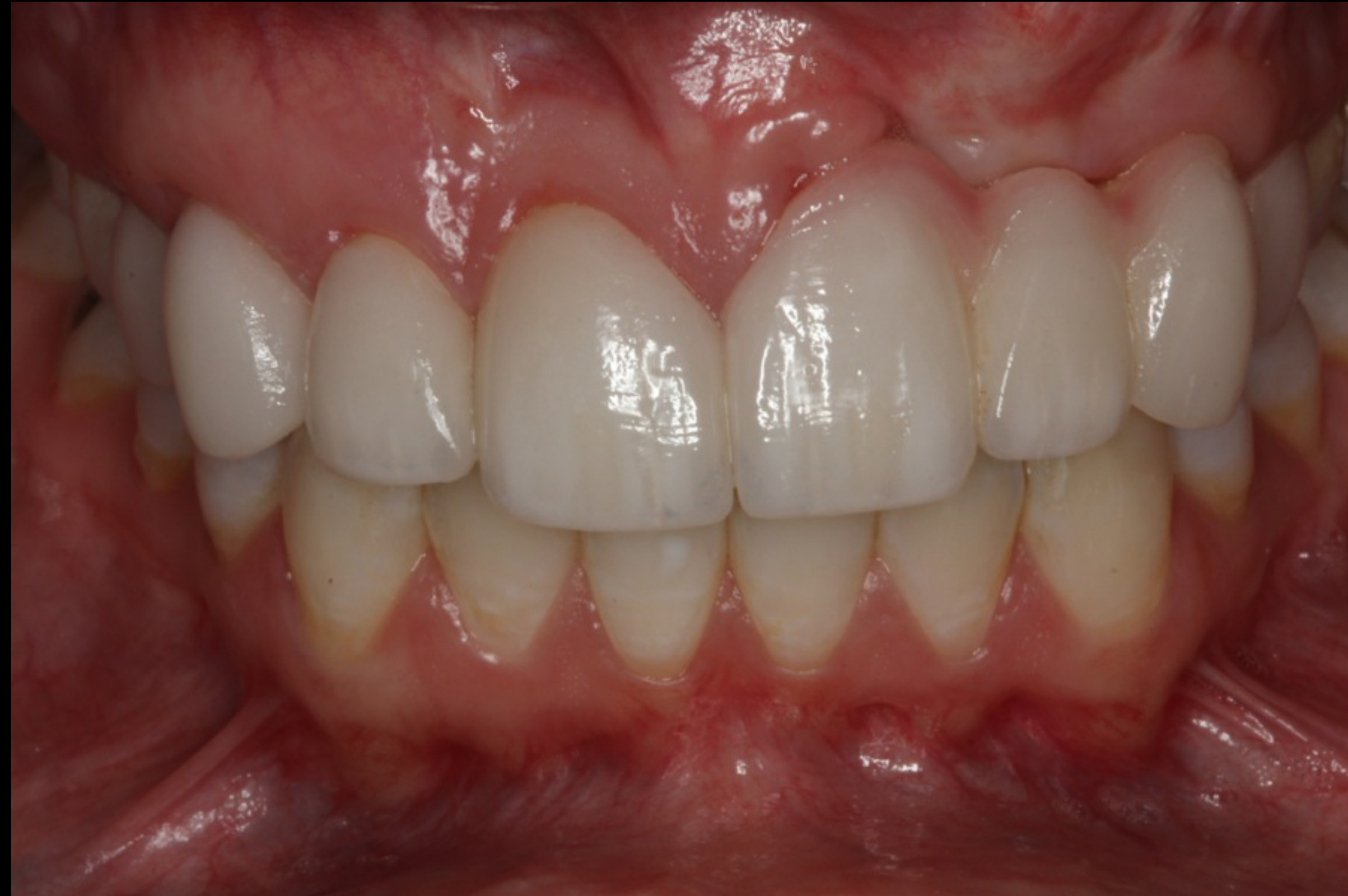

*June 2013*

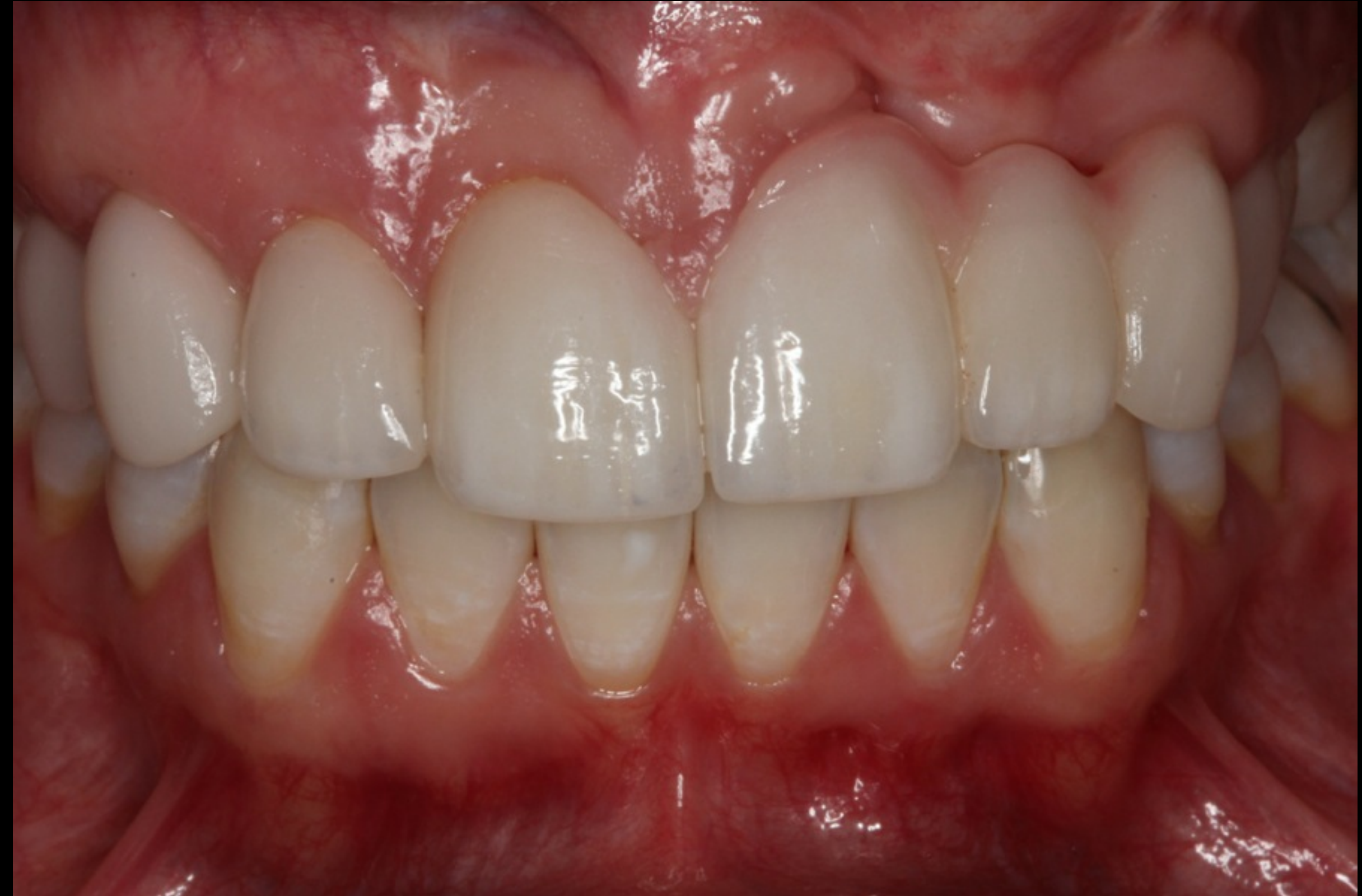*Final Radiographs*



**2 Year Post Surgical**



**3 Year Post Surgical**



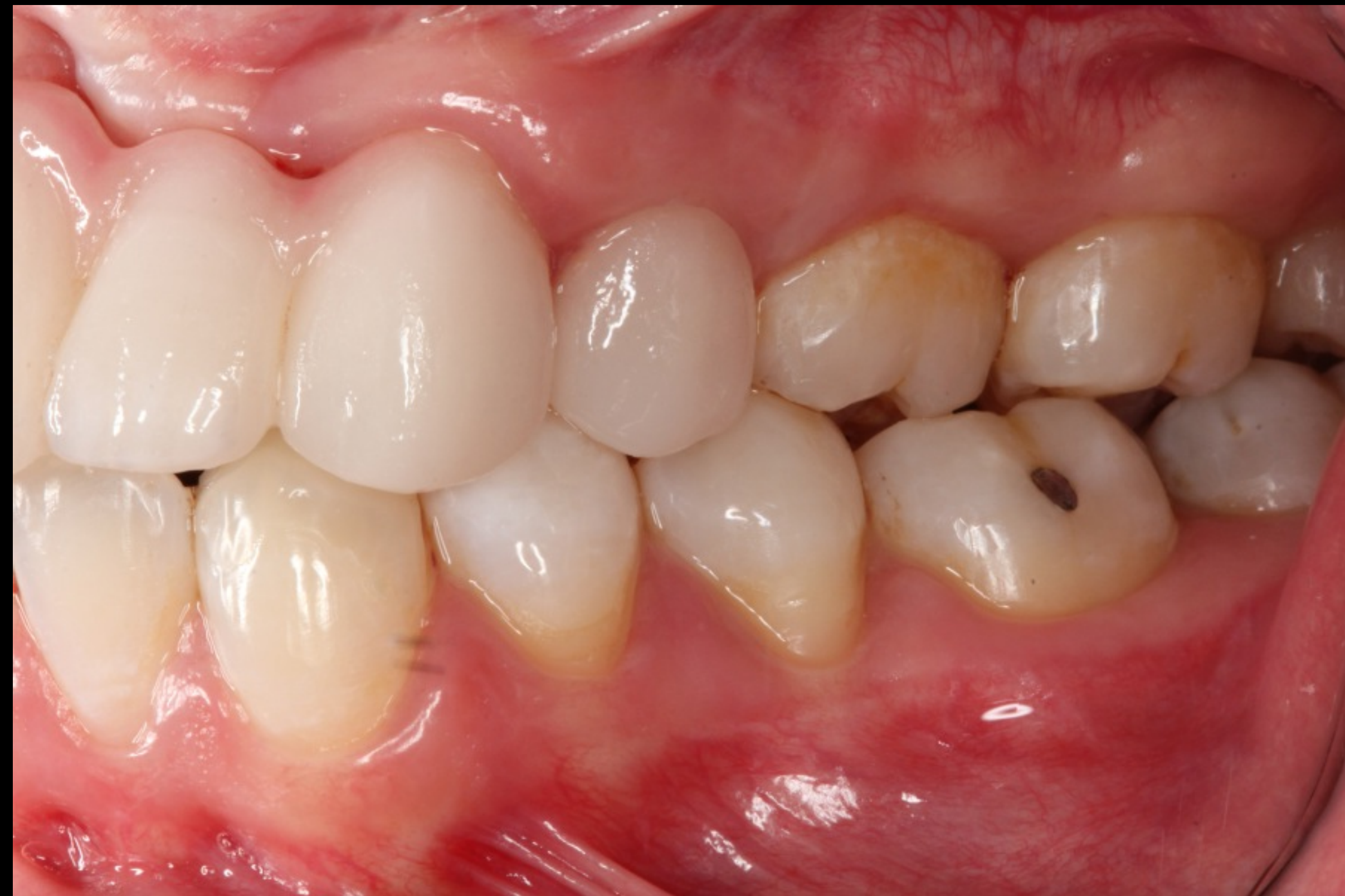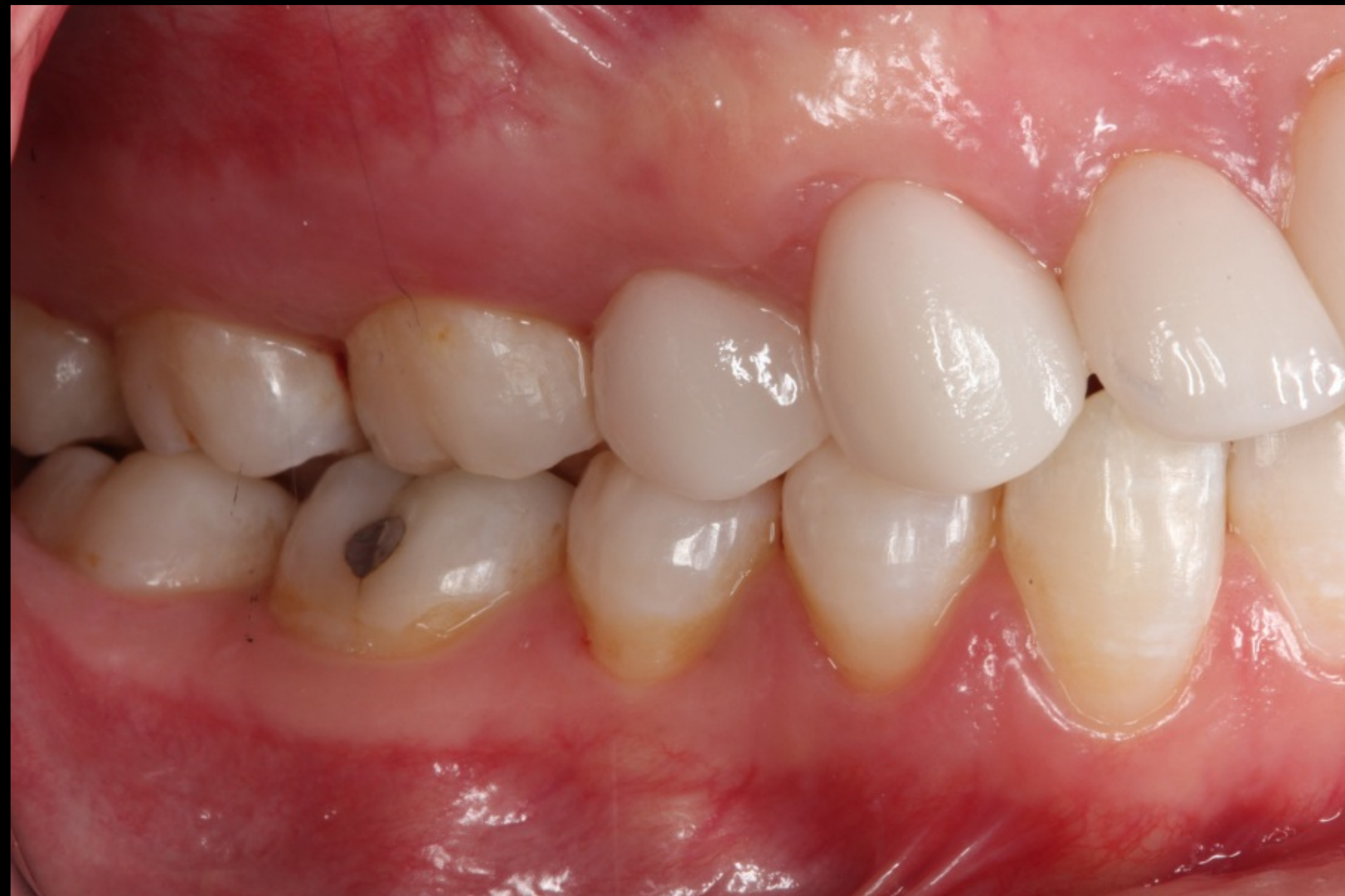*Final Outcome*

*2 & 3 Year Follow-up*



# 3 Year Post Surgical

*Final Outcome*



*3 Year Follow-up*